



## Standards and Guidelines

## SCAI Expert Consensus Statement on the Management of Calcified Coronary Lesions

Robert F. Riley, MD, FSCAI <sup>a</sup>, Mitul P. Patel, MD, FSCAI <sup>b</sup>, J. Dawn Abbott, MD, FSCAI <sup>c</sup>, Sripal Bangalore, MD, FSCAI <sup>d</sup>, Emanouil S. Brilakis, MD, PhD, FSCAI <sup>e</sup>, Kevin J. Croce, MD, PhD, FSCAI <sup>f</sup>, Darshan Doshi, MD, MS <sup>g</sup>, Prashant Kaul, MD, FSCAI <sup>h</sup>, Kathleen E. Kearney, MD, FSCAI <sup>i</sup>, Jimmy L. Kerrigan, MD, FSCAI <sup>j</sup>, Margaret McEntegart, MD, PhD <sup>k</sup>, Akiko Maehara, MD, FSCAI <sup>k,l</sup>, Jennifer A. Rymer, MD, FSCAI <sup>m</sup>, Nadia R. Sutton, MD, FSCAI <sup>n,o</sup>, Binita Shah, MD, MS, FSCAI <sup>d,p,\*</sup>

<sup>a</sup> Overlake Medical Center, Bellevue, Washington; <sup>b</sup> VA San Diego Healthcare System, San Diego, California; <sup>c</sup> Lifespan Cardiovascular Institute, Providence, Rhode Island; <sup>d</sup> NYU Grossman School of Medicine, New York, New York; <sup>e</sup> Minneapolis Heart Institute, Abbott Northwestern, Minneapolis, Minnesota;

<sup>f</sup> Brigham and Women's Hospital, Boston, Massachusetts; <sup>g</sup> Massachusetts General Hospital, Boston, Massachusetts; <sup>h</sup> Piedmont Heart Institute, Atlanta, Georgia; <sup>i</sup> University of Washington, Seattle, Washington; <sup>j</sup> Ascension St. Thomas Heart, Nashville, Tennessee; <sup>k</sup> New York-Presbyterian Hospital/Columbia University Irving Medical Center, New York, New York; <sup>l</sup> Cardiovascular Research Foundation, New York, New York; <sup>m</sup> Duke University Medical Center, Durham, North Carolina; <sup>n</sup> Vanderbilt University Medical Center, Nashville, Tennessee; <sup>o</sup> Vanderbilt University, Nashville, Tennessee; <sup>p</sup> VA New York Harbor Healthcare System, New York, New York

## ABSTRACT

The prevalence of calcification in obstructive coronary artery disease is on the rise. Percutaneous coronary intervention of these calcified lesions is associated with increased short-term and long-term risks. To optimize percutaneous coronary intervention results, there is an expanding array of treatment modalities geared toward calcium modification prior to stent implantation. The Society for Cardiovascular Angiography and Interventions, herein, puts forth an expert consensus document regarding methods to identify types of calcified coronary lesions, a central algorithm to help guide use of the various calcium modification strategies, tips for when using each treatment modality, and a look at future studies and trials for treating this challenging lesion subset.

## Table of Contents

Introduction .....	1
Methods .....	2
Coronary artery calcification.....	2
Identification of calcified coronary lesions.....	2
Calcified nodules .....	2
Long calcified lesions.....	4
Chronic total occlusion interventions.....	4
In-stent restenosis.....	4
Post-coronary artery bypass surgery.....	4
Treatment modalities for calcified CAD.....	6
Balloons.....	6
Rotational atherectomy .....	6
Orbital atherectomy.....	7
Laser atherectomy.....	8
Intravascular lithotripsy .....	8
Specific lesion subsets .....	9

Treatment algorithm for calcified CAD.....	10
Emerging trials and therapies.....	11
Conclusions .....	12
Declaration of competing interest.....	12
Funding sources .....	12
References.....	12

## Introduction

With the increasing burden of comorbidities associated with vascular calcification, the prevalence of coronary artery calcification (CAC) related to obstructive coronary artery disease (CAD) has also increased. Percutaneous coronary intervention (PCI) of calcified CAD is associated with lower procedural success and increased risk for both early and late complications because coronary calcification can impede

**Abbreviations:** CAC, coronary artery calcification; CN, calcified nodule; ISR, in-stent restenosis; IVL, intravascular lithotripsy; IVUS, intravascular ultrasound; MACE, major adverse cardiovascular event; OA, orbital atherectomy; OCT, optical coherence tomography; PCI, percutaneous coronary intervention; RA, rotational atherectomy.

**Keywords:** calcium; coronary artery disease; percutaneous coronary intervention.

\* Corresponding author: [binita.shah@nyumc.org](mailto:binita.shah@nyumc.org) (B. Shah).

<https://doi.org/10.1016/j.jscai.2023.101259>

Available online XX XXXX

2772-9303/© 2023 The Author(s). Published by Elsevier Inc. on behalf of Society for Cardiovascular Angiography and Interventions Foundation. This is an open access article under the CC BY-NC-ND license (<http://creativecommons.org/licenses/by-nc-nd/4.0/>).

stent delivery and deployment, lead to stent underexpansion and malapposition, and directly damage stents. Intravascular imaging is increasingly recognized as an intraprocedural tool that can identify the extent, phenotype, and location of calcium in the target coronary artery and guide use of calcium modification strategies that may lead to optimal stent deployment with a decreased risk of adverse events. A growing number of adjunctive devices are available to facilitate PCI in calcified lesions, including specialty balloons, atherectomy devices, and intravascular lithotripsy (IVL). Given the increasing prevalence of calcified CAD, the expanding role of intravascular imaging during PCI of calcified CAD, and the expanding portfolio of treatment devices available, the Society for Cardiovascular Angiography & Interventions (SCAI) has developed an expert consensus statement to address the treatment of calcified coronary lesions.

## Methods

This statement has been developed according to the SCAI Publications Committee policies for writing group composition, disclosure, and management of relationships with industry, internal and external review, and organizational approval.<sup>1</sup>

The writing group was organized to ensure diversity of perspectives and demographic characteristics and appropriate balance of relationships with industry. Relevant author disclosures are included in [Supplementary Table S1](#). Before appointment, members of the writing group were asked to disclose financial and intellectual relationships from the 12 months prior to their nomination. A majority of the writing group disclosed no relevant, significant financial relationships. The work of the writing committee was supported exclusively by SCAI, a nonprofit medical specialty society, without commercial support. Writing group members contributed to this effort on a volunteer basis and did not receive payment from SCAI.

Literature searches were performed by group members designated to lead each section, and initial section drafts were authored primarily by the section leads in collaboration with other members of the writing group. Consensus statements on the criteria for coronary calcium modification, tips for each treatment modality for calcified CAD, and the treatment algorithm for calcified CAD were discussed and agreed upon by the full writing group using a modified Delphi process, which required 75% agreement among authors for a consensus. The draft manuscript was peer reviewed in October 2023, and the document was revised to address pertinent comments. The writing group unanimously approved the final version of the document. The SCAI Publications Committee and Executive Committee endorsed the document as official society guidance in November 2023.

SCAI statements are primarily intended to help clinicians make decisions about treatment alternatives. Clinicians also must consider the clinical presentation, setting, and preferences of individual patients when determining the optimal approach.

## Coronary artery calcification

The development of CAC is closely interwoven pathophysiologically with the development of atherosclerosis. The prevalence of CAC increases nearly linearly beginning in middle age, and the vast majority of individuals aged 80 years and older have CAC.<sup>2,3</sup> Other clinical risk factors for the development of CAC include chronic kidney disease, diabetes mellitus, hypertension, tobacco use, high body mass index, inflammation, and a family history of heart disease.<sup>2,4–6</sup>

CAC manifests heterogeneously, ranging from flow-limiting stenoses to partially or nonobstructive lesions limited to the vessel wall, with or without positive remodeling.<sup>7</sup> Calcification can replace the intima and/or develop subintimally. Depending on the phase and nature of

calcification development, CAC may be intermixed in varying proportions with an extracellular and cellular matrix and present as microcalcification (associated with unstable plaques), fibrocalcification, or sheets of variable thickness and concentricity.<sup>8</sup> Hydroxyapatite can also crystallize and develop into nodules with or without a fibrous cap.<sup>8</sup>

## Identification of calcified coronary lesions

CAC is often identifiable preprocedurally by noninvasive cross-sectional imaging. Computed tomography (CT) scans obtained for cardiac or noncardiac indications can provide valuable information about the location and extent of CAC, even when CAC is not quantified by the Agatston method or obtained in the context of a dedicated coronary CT angiogram.<sup>9,10</sup>

CAC may also be detected intraprocedurally by fluoroscopy or intravascular imaging. The accuracy of calcium detection on fluoroscopy depends on the overall volume of calcium (measured by the arc, length, and thickness).<sup>11</sup> The overall sensitivity and specificity of fluoroscopy for detecting the presence of target lesion calcium are 50% and 95%, respectively, when compared with intravascular imaging.<sup>11,12</sup> Fluoroscopy alone lacks sufficient resolution to define the subtype of CAC and, in a small proportion of cases, may overestimate the degree of lesion calcium present.<sup>12</sup>

Intravascular imaging improves detection of CAC; further defines the CAC phenotype with the presence or absence of calcified nodules (CN) and superficial or deep wall calcium; measures calcium extent including arc, length, and thickness; and is associated with improved clinical outcomes for patients undergoing complex PCI when used for PCI optimization.<sup>13,14</sup> The 2021 ACC/AHA/SCAI Coronary Artery Revascularization guidelines gave a 2a, level of evidence B-R, recommendation for the use of intravascular ultrasound (IVUS) “for procedural guidance, particularly in left main or complex coronary artery stenting, to reduce ischemic events” and for the use of optical coherence tomography (OCT) as “a reasonable alternative to IVUS for procedural guidance, except in ostial left main disease.”<sup>15</sup> Using pathology as a gold standard, the diagnostic accuracy of IVUS or OCT to detect dense calcium is high (>90% sensitivity and specificity).<sup>16,17</sup> On IVUS, calcium is seen as bright echoes with acoustic shadowing, while on OCT, calcium appears as a heterogeneous area of low backscatter with low attenuation and clear borders. Both IVUS and OCT can measure the arc and length of calcium, whereas only OCT can accurately measure the thickness of calcium. Although OCT provides higher resolution images, it is more limited in depth of imaging when compared with IVUS and requires blood clearance.

The following morphologic characteristics of calcified plaque when assessed by IVUS are shown to be associated with greater stent expansion (>70%) with the use of calcium modification tools when compared with no calcium modification: (1) 360° arc of calcium; (2) calcium arc of >270° with a length of calcium of 2:5.0 mm; (3) calcium present in a vessel with a diameter of <3.5 mm; and (4) presence of a CN.<sup>18,19</sup> Similarly, independent predictors of stent underexpansion in calcified coronary lesions by OCT include maximum calcium angle, calcium length, and the additional characteristic of calcium thickness.<sup>19</sup> Studies have demonstrated a minimum calcium thickness (<0.5 mm) to be more likely associated with calcium fractures after modification.<sup>20–22</sup> Group consensus on the criteria for coronary calcium modification is shown in [Figure 1](#).

## Calcified nodules

A CN is a mass of calcium characterized by a convex shape in the lumen with an underlying severe calcified plate and can be eruptive with fibrous cap disruption and luminal thrombus.<sup>23–26</sup> Large CNs can be seen as angiographic radiolucent masses mimicking thrombi.<sup>27</sup>

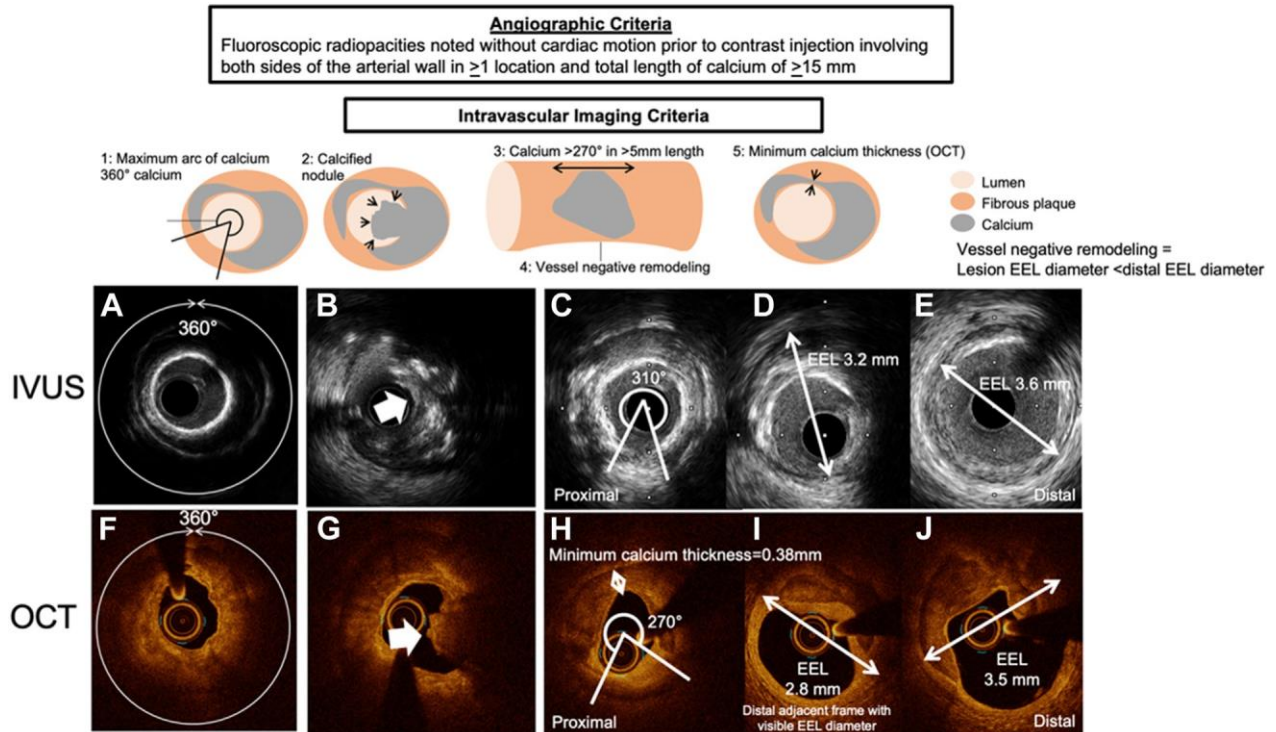


Figure 1.

Criteria for coronary calcium modification (group consensus). Angiographic criteria: fluoroscopic radiopacities noted without cardiac motion before contrast injection involving both sides of the arterial wall in at least 1 location and total length of calcium of at least 15 mm. Intravascular imaging criteria: By both intravascular ultrasound (IVUS) and optical coherence tomography (OCT), the total amount of calcium (calcium arc, thickness, and length) and negative remodeling or small vessel size are associated with stent expansion. OCT can evaluate thickness of calcium and the minimum thickness of calcium of  $<0.5$  mm should be associated with the creation of calcium fracture without calcium modification. IVUS (A) and OCT (F) showed 360° of calcium. (B, G) Calcified nodules. (C) Calcium arc measured is 310°. (D) Frame with visible external elastic lamina (EEL) adjacent to (C), and the EEL diameter measured 3.2 mm. (E) further distal frame and EEL diameter measured 3.6 mm. Proximal EEL diameter smaller than distal EEL diameter in (D) indicates vessel negative remodeling. (H, J) OCT shows similar findings but with added calcium minimum thickness measured 0.38 mm.

Although CNs are present in the minority of obstructive coronary lesions ( $<5\%$ ), the prevalence of CNs was 32% in severely calcified coronary lesions (defined as a maximum calcium angle of  $>270^\circ$ ).<sup>23</sup> CNs are more likely to occur at the hinge motion locations of a coronary artery, in the right coronary artery (RCA), and in patients undergoing chronic hemodialysis. The presence of CNs at the time of PCI is associated with an increase in long-term major adverse cardiovascular events (MACE) compared with calcified lesions without CNs.<sup>28,29</sup> Early

restenosis has been attributed to reprotusion of the CN into the stent.<sup>28,29</sup> OCT can differentiate CNs as eruptive (irregular surface) or noneruptive (CN with overlying fibrous cap) (Figure 2).<sup>24</sup> IVUS may also distinguish details of CNs (shape and surface irregularity), although resolution and depth are limited compared with OCT.<sup>25</sup> Eruptive CNs are associated with worse long-term outcomes despite better acute stent expansion compared with noneruptive CNs, possibly due to a higher risk of eruptive CN reprotusion.<sup>24,26</sup>

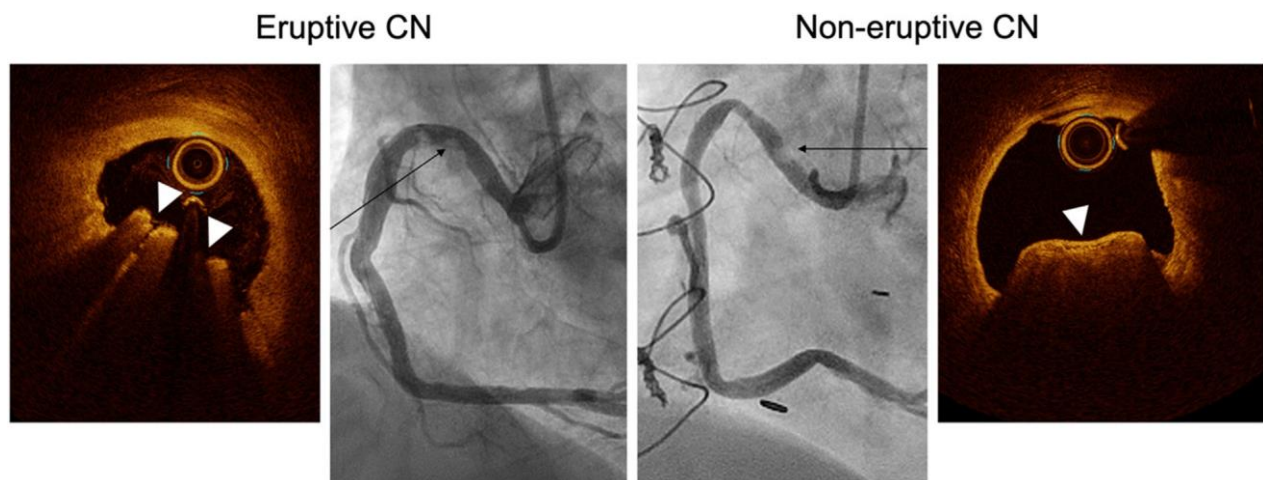
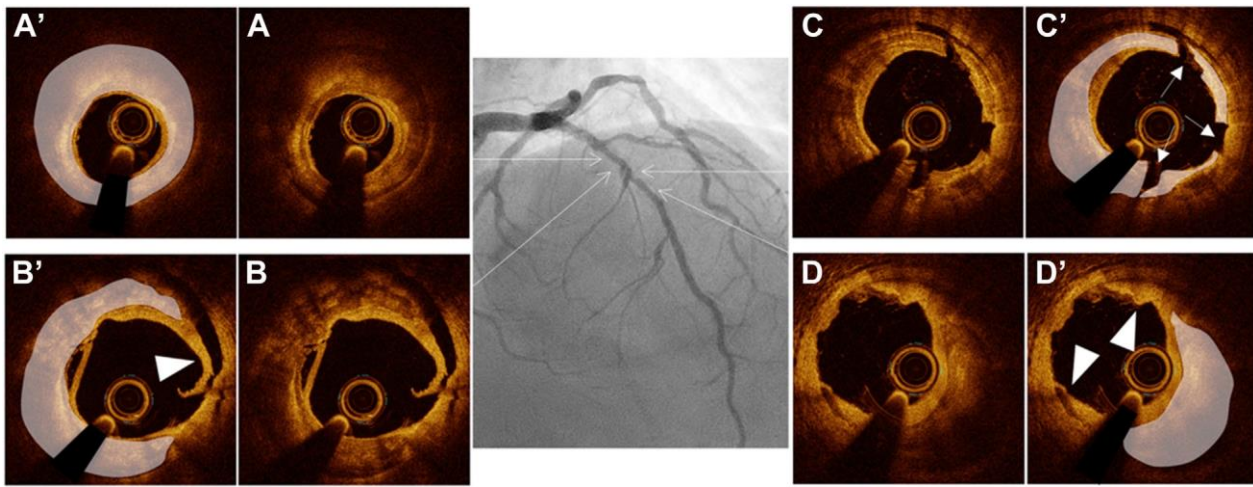


Figure 2.

Eruptive vs noneruptive calcified nodule (CN). Optical coherence tomography (OCT) images illustrate an eruptive CN and noneruptive CN. The eruptive CN is a protruding calcium mass with an irregular shape and strong signal attenuation. The noneruptive CN has a smooth fibrous cap overlying a protruding calcium mass with strong signal attenuation. In both cases, the corresponding coronary angiography demonstrates a radiolucent mass (black arrows).



**Figure 3.** Calcium distribution in a long lesion. Preintervention coronary angiography and optical coherence tomography (OCT) images after 3 mm noncompliant balloon dilatation at 20 atm. (A) Circumferential calcium without fracture requiring further preparation. Because the minimum thickness of calcium measured 0.43 mm, additional angioplasty was performed with a 3.5 mm noncompliant balloon at 20 atm. (B) 180° of calcium with a large dissection in the fibrous plaque (arrowhead). (C) Thin calcium at the site of the most obstructive portion of the lesion, with 3 calcium fractures (white arrows in C). (D) 90° of thick calcium with dissection on both sides of the calcium (arrowhead). Poststent OCT demonstrated calcium fracture with optimal stent expansion (minimum stent area of 6.5 mm<sup>2</sup>). In long lesions, all calcium segments should be confirmed to be fractured on intravascular imaging or yielded to allow full expansion in 2 angiographic views with a 1:1 NC balloon inflation prior to stenting. (A'-D') Same images as (A-D) with annotation. White shaded areas in (A'-D') indicate calcification.

### Long calcified lesions

Patients with long coronary lesions often have diffuse disease and long-standing or uncontrolled CAD risk factors,<sup>30</sup> which increase their risk of long-term adverse cardiovascular events.<sup>31</sup> In the setting of PCI, increased length of CAC segments is associated with an increased risk of stent underexpansion in multiple studies.<sup>18,19</sup> In long lesions, the stenotic and severely calcified segments may not always co-localize. It is important to determine the location of a severely calcified lesion by intravascular imaging to focus the effect of a given calcium modification device on that segment at risk for underexpansion, particularly in areas without severely obstructive plaque (Figure 3).

### Chronic total occlusion interventions

PCI of calcified chronic total occlusion (CTO) lesions has lower procedural success<sup>30,32,33</sup> and is associated with a higher risk of complications compared with that of noncalcified CTO lesions.<sup>34,35</sup> Preprocedural chest CT and intravascular imaging are useful in this setting to understand the distribution and morphology of the calcium and guide the PCI strategy (Figure 4). Calcification of the proximal cap may decrease the success of antegrade wiring and may be identified by intravascular imaging from a side branch when anatomically feasible. During reverse controlled antegrade and retrograde tracking and dissection, intravascular imaging can be used to identify a favorable location (with less calcium) to improve the success of retrograde guide wire reentry.<sup>36</sup>

### In-stent restenosis

In-stent restenosis (ISR) is defined as 2:50% stenosis within the stent at the time of follow-up angiography.<sup>37</sup> Restenosis can occur due to several mechanisms, but in the context of calcium, restenosis may be due to failure of the stent to fully expand at the time of implantation as a result of underlying calcification. Neointimal hyperplasia associated with calcium sheets or nodules within the stent may also occur.<sup>38-41</sup> In a study of 512 patients with second-generation

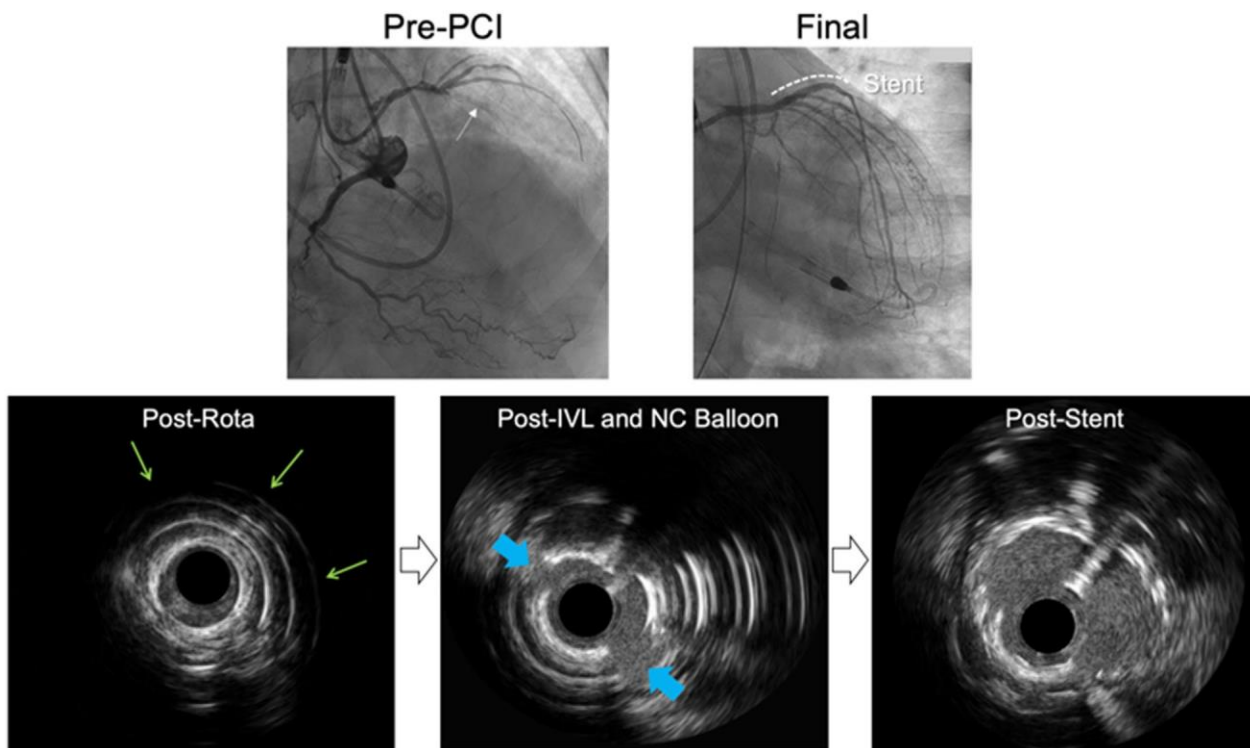
drug-eluting stent (DES) restenosis requiring repeat revascularization, the prevalence of in-stent calcified neointimal hyperplasia was 10% at 5 to 7 years and 20% at >7 years.<sup>40</sup> Similar to de novo calcified lesions, a large arc (>180°) and thick calcium (>0.5 mm) either within the stent or persistent were associated with underexpansion of the second layer of stent<sup>41</sup> (Figure 5).

### Post-coronary artery bypass surgery

Patients with severely calcified coronary arteries showed similar increased long-term mortality rates whether they are treated with PCI or coronary artery bypass graft surgery (CABG).<sup>42</sup> With the exception of I study, data support accelerated progression of atherosclerosis in grafted coronary arteries.<sup>43-46</sup> Intravascular imaging studies have further demonstrated lesions in the native coronary arteries proximal to bypass graft anastomoses to have a greater degree of calcification, higher prevalence of CNs, and greater negative remodeling when compared with patients without prior CABG.<sup>47,48</sup>

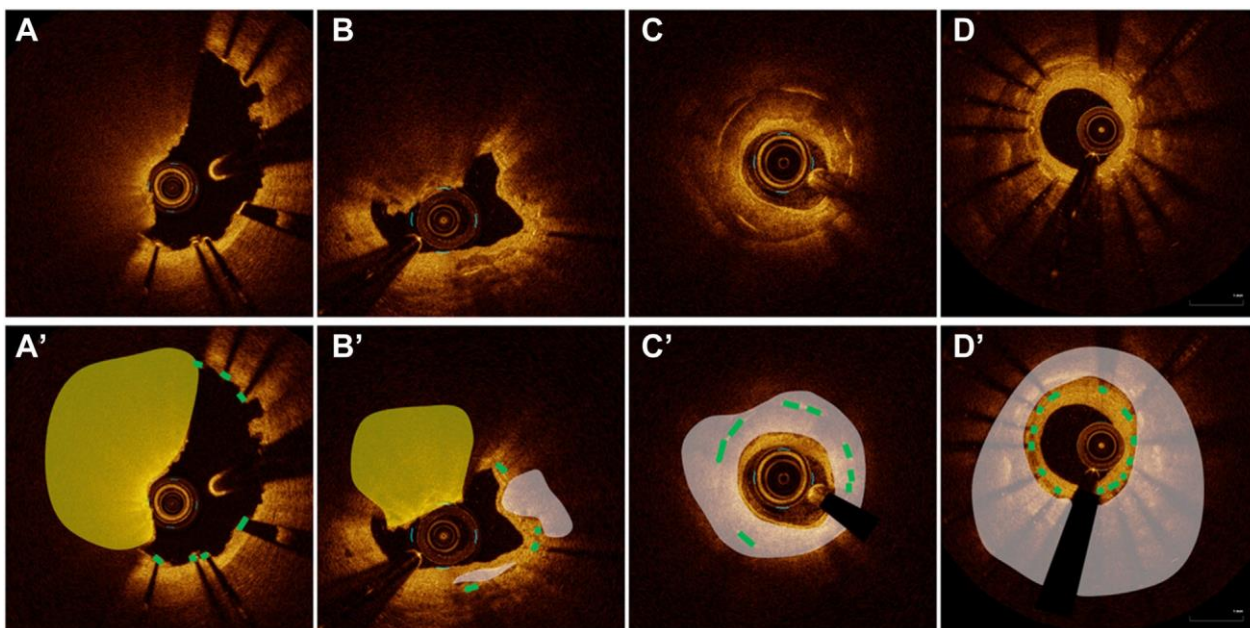
### Highlights

- The overall sensitivity and specificity of fluoroscopy to detect target lesion calcium are 50% and 95%, respectively, when compared with intravascular imaging.
- Fluoroscopy lacks sufficient resolution to define the subtype of CAC and, in a small proportion of cases, may overestimate the degree of calcium present, emphasizing the important added value of intravascular imaging.
- Both IVUS and OCT can measure the arc and length of calcium, whereas only OCT can accurately measure the thickness of calcium (group consensus is to evaluate minimum, rather than maximum thickness as part of calcium criteria).
- Early restenosis after treatment of CN has been attributed to reprotrusion of the CN into the stent.
- The presence of CNs at the time of PCI is associated with increased MACE, including an increased risk of perforation.
- Severe calcium in CTO PCI is predictive of lower success and higher complication rates.



**Figure 4.**

Balloon-uncrossable chronic total occlusion lesion treated with rotational atherectomy and intravascular lithotripsy. Coronary angiogram shows calcification in the occluded segment (white arrow) of a chronic total occlusion in the proximal left anterior descending artery. After successful antegrade guide wire escalation, no device was able to cross. Rotational atherectomy (RA) was performed, followed by intravascular lithotripsy (IVL). Intravascular ultrasound (IVUS) after RA demonstrated circumferential calcium with reverberation (equidistant white circles, indicated by green arrows). A post-IVL IVUS image shows 2 calcium fractures (blue arrows). A poststent IVUS image shows good stent expansion (stent area of  $6.5 \text{ mm}^2$ ).



**Figure 5.**

Stent failure with calcified plaque. (A) Optical coherence tomography (OCT) image of a stent implanted 5 weeks prior. A protruding mass with strong attenuation indicates a calcified nodule (CN). Because neoatherosclerosis would not accrue in such a short time span, it was interpreted as reprotrusion of a CN through the recently implanted stent. (B) CN found in the stent placed many years prior was interpreted as calcified neoatherosclerosis with a CN. (C) Thick calcium within and outside of an old stent (white area) diagnosed as neoatherocalcification. Because of the thick calcium, calcium modification is necessary before stenting. (D) Old underexpanded stent with limited neointimal hyperplasia causing restenosis and thick, circumferential calcium outside the stent. (A'-D') are the same images as (A-D), with annotation. White areas indicate calcium; yellow areas indicate a CN, and the green lines indicate stent struts.

## Treatment modalities for calcified CAD

Treating calcified, obstructive CAD with PCI is associated with increased procedural complexity and risk compared with noncalcified CAD because of the presence of comorbid conditions and the unyielding nature of the CAC. When CAC is present at the time of PCI, there are increased risks of MACE due to stent underexpansion,<sup>49</sup> including target vessel failure (TVF), stent thrombosis, and ISR.<sup>49–52</sup> Given the decreased procedural success rates and increased periprocedural risks, several tools have been developed to facilitate treating these lesions.

### Balloons

Semicompliant and noncompliant balloons. Conventional balloon angioplasty, with either a semicompliant or noncompliant (NC) balloon, often can be used to modify less severely calcified lesions or to prepare heavily calcified lesions for further modification. Conventional balloon angioplasty does not remove calcium but rather creates dissections in the media and disrupts thin calcium to increase plaque elasticity and allow stent expansion.<sup>53</sup>

Conventional balloon angioplasty is typically indicated for lesions with a mild degree of calcium<sup>54</sup>; however, it has several limitations in the setting of calcified coronary lesions. First, although NC balloons can be expanded to high pressures (20–24 atm), balloon expansion may occur eccentrically in the noncalcified segment toward the most compliant vessel wall and may result in vessel perforation or flow-limiting dissection.<sup>54</sup> Second, a conventional balloon may be unable to stay within the severe lesion and, instead, “watermelon seed” toward nondiseased segments of the vessel. Third, because semicompliant and NC balloons have a single-layer structure, nonuniform expansion secondary to protruding calcium may increase the risk of balloon rupture, severe uncontrolled dissection, and/or vessel perforation.

Cutting and scoring balloons. The cutting balloon (CB) is a less-compliant balloon that utilizes multiple microsurgical blades along its longitudinal surface to make small shallow incisions and sever elastic and fibrotic continuity of calcified plaque with low pressure inflations. By creating predictable dissection planes in the vessel wall, these incisions result in injury localized to the site of the cutting and fractures in the calcium to allow for improved and symmetric stent expansion. The blades also allow for less balloon slippage.<sup>55</sup>

The Cutting balloon to Optimize Predilation for Stenting (COPS) trial compared high-pressure (18–20 atm) inflation of CB with NC balloon angioplasty in patients with severe CAC undergoing PCI. The primary outcome of minimum stent area (MSA) at the site of calcium was higher posttreatment with CB than that with NC balloon (8.2 mm<sup>2</sup> vs 7.3 mm<sup>2</sup>;  $P \frac{1}{4} .035$ ), although the final MSA was not different between the 2 arms.<sup>56</sup> The currently available Wolverine CB (Boston Scientific) was designed with a lower profile platform to increase deliverability when compared with the original CB.

Scoring balloons were primarily designed to be delivered more easily and exert less mechanical trauma on the vessel wall than CBs<sup>54</sup>; however, a recent analysis demonstrated that the Wolverine CB was more deliverable than the Lacrosse NSE ALPHA scoring balloon (NIPRO) (90.8% vs 79.5%;  $P \frac{1}{4} .006$ ) with no difference in cross-sectional area gain between groups.<sup>57</sup>

Currently, there are 3 scoring balloons available in the United States. The AngioSculpt scoring balloon (Philips) consists of a semicompliant balloon with 3 to 4 helical nitinol-based scoring elements. The Chocolate XD Balloon (Teleflex) is a semicompliant balloon encased on a nitinol-constraining cage, which, during inflation, causes the balloon to form a series of segmented pillows and grooves along the lesion. The balloon is designed with the intent that the pillows to apply force and

create small dissections while the grooves relieve the stress and potentially prevent the dissections from propagating. The Scoreflex NC scoring balloon (OrbusNeich) is an NC scoring balloon with an integrated nitinol wire that acts as the first scoring element and uses the delivery guide wire as the second scoring element.

High-pressure balloons. The OPN balloon (SIS Medical) is a double-layer balloon that can be dilated to very high pressures. In a retrospective analysis of 326 undilatable lesions treated with the OPN balloon, lesions were divided into 2 groups based on the final inflation pressure required to adequately dilate the lesion: lesions that yielded at 30–40 atm and those that required pressures >40 atm to yield. Lower pressures were adequate in 53% of the lesions, whereas the remaining 47% of lesions required a pressure of >40 atm to achieve optimal expansion. Angiographic success (residual angiographic stenosis <30%) was achieved in 97.5%, and procedural success was observed in 96.6%; however, 3 patients experienced vessel perforation after balloon inflation.<sup>58</sup> Undersizing the OPN balloon for predilation by 0.5 mm and using a 1:1 sizing strategy for postdilation are recommended.<sup>59</sup>

Limitations of the OPN balloon include increased risk of vessel perforation, particularly when used before stent placement. Unlike NC balloons, the OPN balloon increases in size at high pressures. In addition, its relatively bulky profile and extra stiffness due to the twin layered technology make it difficult to re-cross with the balloon once it has been inflated.<sup>58</sup>

### Consensus Tips for Balloons

- CB should be used primarily to create fractures in calcium, rather than to optimally dilate the lesion, due to increased risk for perforation. To reduce the risk of perforation, it is recommended to (1) decrease the size of the CB by 0.5 mm compared with the reference artery diameter<sup>56</sup> and follow CB inflation with a 1:1 sized NC balloon; and (2) if multiple inflations with a CB are performed, move the CB slightly proximally or distally to cut in different areas.
- CB and scoring balloons have a technical advantage of less slippage than conventional balloons, which may be particularly useful in ostial lesions.<sup>55</sup>
- The rated burst pressure of the OPN balloon is 35 atm, and inflating the OPN balloon to higher pressure is associated with an increased risk of vessel perforation. In de novo lesions, undersize the OPN balloon by 0.5 mm because the balloon increases in size with higher pressures. In lesions with a stent in place, size the OPN balloon 1:1.
- After multiple high-pressure inflations with an NC balloon or inflation of the high-pressure OPN balloon, there may be an adherence of the balloon to the guide wire, and wire position may be lost upon withdrawal of the balloon. Consider using a buddy wire to maintain access in case the guide wire on which the NC or OPN balloon is loaded is withdrawn along with the balloon.

### Rotational atherectomy

Rotational atherectomy (RA) with the Rotablator RA System (Boston Scientific) uses a high-speed rotational device with a diamond-tipped burr designed to preferentially ablate calcified atherosclerotic plaque according to the principle of differential cutting, sparing the compliant elastic tissue. The ablated tissue fragments are 2.0 to 10.0  $\mu\text{m}$  in size and are theoretically able to pass through the distal coronary microcirculation.<sup>60</sup> The metallic burr, ranging in size from 1.25 to 2.5 mm, is mounted over an advancer driveshaft (RotaLink) connected to a motor that converts compressed gas into rotational energy. The current generation RotaPro device has several features to improve usability, including single-operator performance.

### Consensus Tips for Rotational Atherectomy

- The recommended burr size/artery ratio is 0.4 to 0.6. Typically, a 1.5-mm burr can be used for most arteries  $\leq 3$  mm in diameter and a 1.75-mm burr for those  $> 3$  mm. Due to increased risk of entrapment, a 1.25-mm burr is not recommended as the first burr.
- Different guide catheter sizes are required for the different RA burr sizes.
  - The 1.25- and 1.5-mm burrs require a 6F guide catheter.
  - The 1.75-mm burr requires a larger 6F guide catheter (0.071-inch inner diameter) or 7F guide catheter.
  - The 2.0 mm burr requires a larger 7F guide catheter (0.081-inch inner diameter) or 8F guide catheter.
  - The 2.15-mm burr requires an 8F guide catheter.
- The RotaWire guide wire is 0.009 inches in diameter that tapers to 0.005 inches before terminating in a 0.014-inch spring tip. The RotaWire is available in 2 types: floppy and extra support.
  - The more flexible and torqueable floppy guide wire reduces vessel straightening, thereby minimizing guide wire bias and facilitating ablation of lesions at the greater curvatures of angulated segments; however, it is easier to kink and requires more careful manipulation.
  - The stiffer extra support guide wire offers more support for delivery, favorably biases the guide wire toward eccentric calcified plaques (particularly in angulated segments), and augments eccentric plaque modification; however, there may be an increased risk of perforation with the RotaWire extra support vs RotaWire floppy guide wire owing to the heightened guide wire bias.
- Primary wiring of the lesion with a RotaWire is often feasible.
- Keep the distal tip of the RotaWire in the field of view and keep the radiopaque distal segment of the RotaWire at least 5.0 mm from the burr at all times to avoid fracture of the radiopaque 0.014-inch segment by the burr.
- RA is performed with a continuous intracoronary saline infusion of a lubricant solution (RotaGlide) through the rotaburr system to reduce friction and heat generation. RotaGlide is contraindicated in patients with allergy to egg or olive oil. Alternatives to RotaGlide include off-label use of a saline infusion mixed with heparin  $\pm$  vasodilators (eg, 10,000 units of unfractionated heparin with or without 400.0  $\mu$ g nitroglycerin and 10.0 mg verapamil in 1 L normal saline).<sup>63-65</sup>
- RA should be performed using a pecking motion with short duration of ablation ( $< 30$  seconds) and a short ablated segment.
- Avoid burr deceleration  $> 5000$  rpm to reduce the risk of complications (eg, slow flow and burr entrapment).
- To reduce the risk of wire fracture when ablating the same spot for multiple runs, move the RotaWire more proximally or distally so that the burr is not continually ablating on the same spot of the wire.<sup>66</sup>
- If a lesion cannot be crossed despite optimal technique, use higher rotational speeds, downsize the burr, use a more supportive guide catheter, or add a guide catheter extension.
  - The 1.25-mm burr requires a 7F guide catheter extension.
  - The 1.5-mm and 1.75-mm burrs require an 8F guide catheter extension.
  - A 2.0-mm burr cannot be accommodated by any currently available guide catheter extension.
- The need for temporary pacing is low with the currently used smaller burrs<sup>67</sup>; however, patients with baseline conduction disorder or lower physiologic reserve (eg, clinically significant valvular disease and low left ventricular ejection fraction) may benefit from placement of a temporary pacemaker to minimize transient bradycardia and ischemia when performing RA in a dominant RCA or circumflex artery.
- A final polishing run with no decelerations and little or no resistance should be performed before removing the burr.

The Rotational Atherectomy Prior to Taxus Stent Treatment for Complex Native Coronary Artery Disease (ROTAXUS) trial<sup>61</sup> randomized 240 patients with calcified native coronary lesions to stent placement with or without RA for lesion preparation. The trial showed improved acute lumen gain ( $1.56 \pm 0.43$  mm vs  $1.44 \pm 0.49$  mm;  $P = .01$ ) and increased rates of successful stent deployment in the RA group (92.5% vs 83.3%;  $P = .03$ ). The Comparison of Strategies to PREPARE Severely Calcified Coronary Lesions (PREPARE-CALC) trial<sup>62</sup> randomized 200 patients with severely calcified native coronary artery lesions to either RA or vessel preparation with CB/scoring balloons. RA led to not only longer fluoroscopy times ( $22.8 \pm 21.9$  min vs  $18.1 \pm 16.7$  min;  $P = 0.04$ ) but also a higher rate of procedural success (98% vs 81%;  $P = .0001$ ). Although not powered for clinical outcomes, there were no differences in myocardial infarction, ISR, target lesion revascularization (TLR), stent thrombosis (ST), or MACE at 9-month follow-up in either trial. Limitations of the abovementioned trials are that the entry criteria of calcium severity were based on angiography and not intravascular imaging, and there was crossover from the non-RA group to the RA group in 16% of patients.

The 2021 ACC/AHA/SCAI Coronary Artery Revascularization guidelines<sup>15</sup> gave a 2a, level of evidence B-R, recommendation for the use of RA in patients with heavily calcified lesions, noting that RA “can be useful to improve procedural success.” The guidelines further note that “despite the lack of data to support improved long-term outcomes with RA, RA remains an important tool in certain situations to properly ‘prepare’ a lesion for stenting.”

### Orbital atherectomy

The orbital atherectomy (OA) system (Diamondback 360, Abbott) has a 1.25-mm diamond-coated crown that is eccentrically mounted 6.0 mm from the tip (nose cone) of the device, allowing for bidirectional atherectomy. OA works through centrifugal force and surface friction, creating elliptical orbits that change the compliance of calcified vessels by altering the depth of calcium and creating microfractures. There are 2 speeds of the OA crown, 80,000 and 120,000 rpm; the higher rotations-per-minute setting allows for a larger diameter ablation field (2:3.0 mm).

Evidence supporting the use of OA comes from the Evaluate the Safety and Efficacy of OAS in Treating Severely Calcified Coronary Lesions (ORBIT) trials. In ORBIT I,<sup>68</sup> 50 patients from 2 centers in India with de novo calcified coronary lesions were prospectively enrolled and treated with OA and stent placement. The majority, 90%, were male, and the lesions were short with a mean lesion length of 13.4 mm. Device and procedural success were high at 98% and 94%, respectively. In this study, there were 6 dissections observed by angiography and 1 perforation. ORBIT II<sup>69</sup> was a larger (n = 443), prospective, nonrandomized, multicenter study of OA in the United States. The primary efficacy end point of residual stenosis  $< 50\%$  after stent placement without in-hospital MACE with the OA device was higher than the performance goal (88.9% vs 82%). The incidence of coronary dissection was much lower than ORBIT I at 2.3%, as was the perforation rate of 0.9%.

The 2021 ACC/AHA/SCAI Coronary Artery Revascularization guidelines<sup>15</sup> gave a 2b, level of evidence B-NR, recommendation for the use of OA in patients with heavily calcified lesions, stating that OA “may be considered to improve procedural success.” Complications rates with OA are similar to complication rates with RA.<sup>70</sup>

### Consensus Tips for Orbital Atherectomy

- The OA device requires at least a 6F guide catheter or a 7F system if guide extension use is planned.
- Primary wiring of the lesion with an OA ViperWire Advance guide wire with or without the FlexTip (nitinol core 0.012-inch body and 0.014-inch tip) is often feasible.
- Keep the distal tip of the ViperWire in the field of view and at least 5 mm from the OA drive shaft tip to avoid fracture of the distal portion of the wire that is thicker than the proximal portion.
- Nitroglycerin is generally given before the first run and intermittently through the device tubing side port or the guide catheter as hemodynamics tolerate to minimize slow flow.
- The optimal technique for OA differs from RA and requires a smooth forward or backward motion at approximately 1.0 mm/s to achieve greater lumen diameter gain compared with faster rates of motion. The number of runs is also highly correlated with greater achievable lumen gain.
  - Never use force during antegrade or retrograde treatment.
  - Observe 1:1 motion between the crown and advancer knob; if the crown is not moving, do not push harder because this may lead to a malfunction or complication.
- Start at 80,000 rpm in all vessels, and listen for the audible pitch change that occurs when the device contacts calcification in the vessel and stops when the ablative ability of the device is reached. In vessels with diameter of 2.3:3.0 mm, the speed can be increased to 120,000 rpm to achieve a larger lumen gain.
- OA treatment intervals should not exceed 30 seconds, and the maximum total treatment time with the same crown should not exceed 5 minutes.
- Allow a rest time between runs that is at least as long as the treatment time, and rest in a nonocclusive position within the vessel.
- Transient conduction disorders can occur when a dominant RCA or circumflex artery is treated, and either prophylactic aminophylline or a temporary pacemaker can be considered.
- Treatment of ostial lesions with OA is associated with a risk of aortic dissection. However, OA can be considered cautiously by experienced operators if the device is advanced distal to the lesion using glide assist and actuated retrogradely without allowing the crown to have an unrestricted orbit at the ostium.<sup>71</sup>

### Laser atherectomy

Excimer laser coronary atherectomy (ELCA) uses a xenon chloride system to generate ultraviolet light via a laser catheter to modify plaque constituents without substantial thermal injury. The ELCA system has 3 mechanisms of action: (1) ablation—where the laser light ablates mixed tissue morphologies at the molecular level by breaking molecular bonds; (2) acoustic mechanical modification of plaque compliance—where an acoustic pressure wave impacts rigid materials and increases vessel compliance; and (3) cavitation—where the laser creates a fluid cavitation bubble that is more likely to debulk soft plaque/thrombus. Other advantages of ELCA include (1) use with any workhorse angioplasty guide wire, (2) ability to use with multiple guide wires in place to protect bifurcations, (3) ability to adjust settings (fluence and rate), and (4) minimal risk of entrapment.

Clinical data for ELCA in randomized trials are scant, conducted with a prior version of the technology, and/or outdated with respect to current practices including routine use of dual antiplatelet therapy and stents.<sup>72</sup> The photochemical laser properties are used for tissue ablation in the context of refractory thrombus, ISR, degenerating saphenous vein graft interventions, and acute vessel closure.<sup>73,74</sup> This differential property of ELCA distinguishes it from the differential cutting of other atherectomy devices when dealing with softer luminal tissues that require modification. ISR due to calcium-related stent unexpansion may

require off-label use of contrast to maximize the photomechanical properties.<sup>75</sup> The ability to advance the laser catheter over a coronary guide wire facilitates crossing device-uncrossable lesions even if alternative forms of atherectomy are subsequently used. ELCA is effective in fibrotic lesions such as suture lines or ISR but has limited impact on severe calcification.<sup>54</sup>

### Consensus Tips for Excimer Laser Coronary Atherectomy

- Although the manufacturer recommends starting with lower fluence and pulse rate owing to theoretical risk of vessel dissection or perforation, the maximum available settings (80 mJ/mm<sup>2</sup> and 80 hertz rate for the 0.9 mm laser catheter) are usually used when treating calcified lesions because fluence setting impacts the size of the vapor bubble.
- Catheter diameter is chosen to approximate two-thirds of vessel size.
- ELCA ablative capacity is time dependent, so slowly advance the catheter at <1.0 mm/s to maximize effectiveness.
- To ablate tissue, use the laser in a forward-only direction to harness the front-facing laser ablative energy.
- To alter lesion compliance, operate the laser bidirectionally because the acoustic mechanical energy emanates in a 360° arc from the catheter tip.
- To reduce the risk of perforation, carefully watch the nose cone of the laser when advancing. If the catheter stalls and the nose deflects, the laser will be pointing toward the adventitia instead of being coaxial with the vessel.
- Off-label injection of contrast when the laser is on augments cavitation and generation of acoustic mechanical energy that fractures calcium.<sup>75</sup> This may be useful in-stent underexpansion due to calcium. However, there is an associated increased risk of no-reflow or perforation.
- In rare cases, the off-label use of laser with contrast can lead to separation of the distal radiopaque marker band from the catheter.<sup>76</sup>
- ELCA on a polymer-jacketed guide wire should be avoided because of potential of damage to the polymer.

### Intravascular lithotripsy

The Shockwave Medical Intravascular Lithotripsy System (Shockwave Medical) is a balloon with emitter pairs that emit pulsatile sonic pressure waves that selectively interact with calcium. Within the 12.0-mm balloon, the first emitter is offset 4.0 mm from the distal balloon marker, with 6.0 mm between emitters. The balloon is placed within the target lesion and inflated to 4 atm to deliver 10 shockwaves. When the waves interact with calcium, they amplify to an effective 50 atm. Previous guidance to inflate the balloon to 6 atm after the delivery of each set of pulses has largely been abandoned because this is now believed to increase the risk of balloon rupture.

Intravascular imaging and micro-CT analyses have demonstrated that IVL results in both superficial and deep, radial and longitudinal, macrofractures, and microfractures.<sup>77</sup> The original coronary IVL device (C2) delivers up to 80 pulses, whereas the next generation device (C2b) delivers up to 120 pulses.

Approval for IVL use was granted in the United States in 2021 after completion of Disrupt CAD III, a prospective, single-arm, multicenter study of 384 patients.<sup>78</sup> Device delivery was successful in 95% of cases, and procedural complication rates were very low, with no cases of slow flow/no-reflow and only isolated incidents of dissection, perforation, and abrupt closure.<sup>77</sup> Low rates of ST (0.8%) and target lesion failure (7.6%) were observed at 30 days. MACE at 1 year occurred in 14% of patients, with myocardial infarction in 10.5%, ischemia-driven TLR in 4.3%, and target lesion failure in 12% of study participants. These



results were reproduced across multiple countries and operators in the pooled analysis of the Disrupt CAD I-IV studies.<sup>70,79</sup> Additionally, while it was anticipated that IVL would be most effective in the presence of concentric calcium, the Disrupt CAD pooled OCT analysis found the efficacy and safety to be consistent whether calcium was concentric, eccentric, or nodular.<sup>70,79,80</sup> Similarly, a recent analysis of the Disrupt CAD studies showed that IVL closed the gap in differential stent expansion parameters for lesions with and without CNs.<sup>81</sup>

IVL may be used in the presence of multiple guide wires (eg, bifurcation lesions) and may also be advantageous in aorto-ostial lesions. While hemodynamically vulnerable patients may not tolerate repeated or prolonged balloon obstruction of coronary flow during delivery of IVL therapy, recent data demonstrate safety and feasibility of IVL in left main coronary artery PCI, and the rate of slow flow/no-reflow is lower with IVL than that with RA or OA.<sup>70,77,82</sup> The off-label use of IVL has also been widely adopted in the treatment of stent underexpansion due to calcium, calcific neoatherosclerosis within the stent, or nodular re protrusion.<sup>83,84</sup> The main limitation of the device, as with the other balloon-based technologies, is deliverability, but this can be mitigated with increasing guide support through guide shape, guide extensions, buddy wires, or other techniques. Overall angiographic complication rates are <0.5%.<sup>85-87</sup>

#### Consensus Tips for Intravascular Lithotripsy

- IVL is best for modifying circumferential calcium in balloon-crossable lesions. Although data show effectiveness of IVL therapy in eccentric and nodular calcium, more pulse delivery may be required in these lesions.
- IVL can be used synergistically with atherectomy devices, especially in longer lesions where there is often more heterogeneity in vessel size and pattern of calcification.<sup>88</sup>
- Longer rest periods between therapy may help prevent hemodynamic compromise when performing IVL in areas that subtend large myocardial distributions (eg, left main lesions).
- IVL can be used with multiple guide wires in place (eg, bifurcation lesions).
- Intravascular imaging can be useful in longer lesions to help determine where pulses are best used. This is also true after atherectomy because atherectomy may modify calcium in smaller diameter vessel segments but is less likely to do so in larger vessel segments.

#### Specific lesion subsets

**Calcified nodules.** The prevalence of CNs reported in patients undergoing plaque modification is 22%-40%.<sup>81,89</sup> A retrospective study of patients undergoing RA observed a 3-fold risk of adverse events in the presence of CNs.<sup>89</sup> In a small propensity-matched study comparing patients with CN, there was no difference in acute lumen gain, malapposition, or target vessel revascularization between those treated with or without RA.<sup>90</sup> Fracture of CNs with OA has been reported, but there are no studies on procedural or clinical outcomes available.<sup>91,92</sup>

The impact of IVL on CNs was assessed in a pooled, patient-level, OCT core laboratory analysis of the Disrupt CAD studies.<sup>81</sup> The prevalence of CNs was 22%, and lesions with CNs had a greater arc and volume of calcium than lesions without CNs. With IVL, there was a numerically higher rate of calcium fracture (78.7% vs 65.2%;  $P \frac{1}{4} .07$ ) in CN vs non-CN lesions with no major complications.<sup>81</sup> Additionally, post-PCI stent expansion measurements were similar in patients with and without CN lesions. With the limited available data and in the absence of comparative studies, IVL is safe and effective, and ablative devices (RA/OA) can be considered as options in the treatment of CN lesions.

#### Consensus Tips for Calcified Nodules

- Intracoronary imaging can identify CN in relation to overall calcium distribution, assess guide wire bias, and provide reference vessel size to assist in calcium modification device selection.
- OA in lesions with a CN often requires slow device motion (1 mm/s), a high number of passes (>5), and higher speed (120,000 rpm).
- To improve RA burr contact with a CN, consider upsizing the burr-to-artery ratio to 0.6 or 0.7 if the lumen is large and there is unfavorable guide wire bias or consider using the RotaWire Extra Support to change the guide wire bias, as needed.
- For IVL, sizing should be 1:1 with the reference vessel diameter, and more pulses are often required to modify CN vs non-CN lesions.
- Prior to stenting, perform NC 1:1 balloon dilatation, ideally followed by imaging to confirm the presence of calcium fracture.

**Chronic total occlusion.** The use of plaque modification in CTOs is higher than that in other lesion subsets but is still, overall, low. In all the published cohorts, devices were predominantly used after intraplaque crossing, with limited data on the efficacy and safety extraplaque. In the multicenter Prospective Global Registry for the Study of Chronic Total Occlusion Intervention (PROGRESS)-CTO registry, atherectomy was used in 3.2% (n  $\frac{1}{4}$  115) of 3607 CTO PCIs, with RA used in 95% of the cases. Procedural success was similar in patients treated with vs without atherectomy, but atherectomy cases were associated with higher rates of tamponade requiring pericardiocentesis.<sup>93</sup> In a more recent analysis of PROGRESS-CTO, IVL was used in 82 cases, and use increased over time to 7% of cases in 2022.<sup>94</sup> IVL was used in procedures with antegrade and retrograde crossing strategies and in vessels that were heavily calcified or balloon undilatable. Perforation occurred in 2.4%, but these were Ellis class 2 and treated conservatively.<sup>94</sup> ELCA use in CTO is generally reserved for impenetrable proximal caps after confirmation of intraluminal position for undilatable lesions or for ISR, but scant data are available.<sup>95</sup> There is also little experience with high-pressure balloons in CTO, and whether the risk of perforation in this setting differs from other devices remains unknown.

#### Consensus Tips for Chronic Total Occlusions

- For intraplaque crossing and device-uncrossable lesions, a microcatheter can be buried in the proximal cap and the guide wire exchanged for a RotaWire guide wire. RA is preferable to OA due to risks associated with device orbit in dissection planes. When dissections are evident, use a 1.5-mm RA burr due to the forward ablative tracking and due to an increased risk of perforation with larger devices.
- When exchange for a RotaWire is not feasible after intraplaque crossing but device-uncrossable lesions, consider ELCA with a 0.9-mm laser and 80/80 settings. ELCA with off-label contrast injection may be required for in-stent undilatable calcified lesions.
- For intraplaque crossing and balloon-crossable lesions, select a device based on intravascular imaging after initial predilatation with a balloon.
- When CTO guide wire crossing is extraplaque and calcium modification is required (after suboptimal balloon angioplasty), consider IVL. RA use has been reported, but published experience is limited.<sup>96,97</sup>

**In-stent restenosis.** In the contemporary era, ISR accounts for 6% to 10% of PCIs. Patients with ISR may have heterogeneous lesions with intimal hyperplasia, neoatherosclerosis, stent underexpansion, and variable calcium distribution. The Angioplasty versus Rotational

atherectomy for Treatment of diffuse In-stent restenosis (ARTIST) trial randomized patients with diffuse bare-metal stent restenosis to balloon angioplasty with or without RA and found no difference in procedural success rates but a lower event-free survival rate in the balloon angioplasty group.<sup>98</sup> Calcium modification for ISR is generally limited to calcific neoatherosclerosis and stent underexpansion due to underlying calcification. Observational series of RA, off-label OA, and ELCA with off-label contrast show use of these devices for ISR is feasible with high rates of procedural success and acceptable complication rates.<sup>99–101</sup> There are several small series reporting efficacy of off-label IVL for ISR.

#### Consensus Tips for In-stent Restenosis

- When feasible, perform intravascular imaging to understand the mechanism of stent failure and distribution of calcium (superficial calcified neoatherosclerosis or calcium behind the stent struts).<sup>102</sup>
- For calcified neoatherosclerosis, the algorithm should be similar to that of de novo lesions (1:1 sized NC balloon, CB/scoring followed by 1:1 sized NC balloon, 0.5 mm undersized high-pressure balloon, atherectomy, or 1:1 sized IVL).
- For calcium behind the stent struts and stent under expansion, consider off-label IVL (1:1 sizing), high-pressure balloon (under size by 0.5 mm), or ELCA (with off-label contrast). Atherectomy can also be considered (burr-to-artery ratio of >0.5 for RA).
- For balloon-uncrossable lesions, consider ELCA (0.9 mm) or RA (0.5 burr-to-artery ratio).

**Aorto-ostial lesions.** Aorto-ostial lesions are located within 3.0 to 5.0 mm from the vessel origin and are associated with a high rate of restenosis, even in the current era of DES.<sup>103</sup> In addition to the technical difficulty of precise stent placement, ostial lesions are often highly calcified, resulting in higher rates of specialty balloon or atherectomy use than nonostial lesions.<sup>103</sup> One study demonstrated a 48% rate of CN in 170 ostial RCA de novo lesions.<sup>104</sup> Adequate vessel preparation and calcium modification can translate into better stent expansion and lower risk of dissections extending into the aorta for aorto-ostial lesions. CB and scoring balloons, high-pressure balloons, and IVL are suitable for ostial lesions, and the ability to extend the device into the aorta is advantageous for anchoring and preventing geographic miss. Data suggest feasibility of RA and OA for ostial lesions.<sup>105,106</sup>

#### Consensus Tips for Aorto-Ostial Lesions

- For balloon-crossable aorto-ostial lesions, consider a CB/scoring balloon, a high-pressure balloon, or IVL for lesion preparation.
- For balloon-uncrossable lesions, consider atherectomy.
  - Consider RA (0.5 burr-to-artery ratio) with coaxial guide support or size up guide catheter by IF from required burr size to minimize catheter ablation.
  - Treatment of ostial lesions with OA is associated with a risk of aortic dissection. However, OA can be considered cautiously by experienced operators if the device is advanced distal to the lesion using glide assist and actuated retrogradely without allowing the crown to have an unrestricted orbit at the ostium.<sup>71</sup>

**Bifurcation lesions.** Calcified bifurcation lesions pose unique challenges, including predisposition to plaque shift, acute side branch closure, and suboptimal stent delivery and deployment. Calcification may be present in both the main branch and side branch or it may be confined to one or the other. Nonablative approaches (CB or scoring balloons, NC balloons, and IVL) or ELCA can be attempted first when needing to maintain the side branch guide wire. Few studies have

evaluated calcified bifurcation lesions. One single-center case series of calcified bifurcation lesions showed excellent 30-day MACE rate with either OA or RA but shorter procedural and fluoroscopy time with OA compared with RA.<sup>107</sup> In a subgroup analysis of the Comparison of Strategies to Prepare Severely Calcified Coronary Lesions (PREPARE-CALC) study, side branch compromise (any stenosis >70% on visual estimation, dissection, or thrombolysis in myocardial infarction flow of <3 on final angiogram) was observed less frequently with RA vs CB/scoring balloons (7% vs 32%;  $P \frac{1}{4} .001$ ).<sup>108</sup> In a large, multicenter analysis of pooled data from 10 high volume centers, OA in bifurcation lesions was associated with low MACE rates similar to those observed for nonbifurcation lesions<sup>109</sup>; however, whether atherectomy was performed in both main and side branches was not reported.

#### Consensus Tips for Bifurcation Lesions

- For calcification restricted to the main branch, the calcium modification strategy is similar to that described for any calcified lesion.
- For side branch calcification alone, consider CB or scoring balloon rather than NC balloons, particularly in the setting of ostial side branch disease, to reduce the risk of slippage.<sup>55</sup> Restrict RA or IVL to major side branches of 2:2.5 mm in diameter.
- For bifurcation lesions with calcification of both main and side branches that require atherectomy, serial RA can be performed in both branches.
  - During RA of the main branch, remove the side branch guide wire to avoid cutting the wire.
  - Determine the sequence of main and side branch RA based on the severity of stenosis and propensity for acute closure.
  - For severely calcified and critically stenosed bifurcation stenosis where there is concern of acute side branch closure during main branch RA, consider techniques that use 2 guide wires, with the side branch guide wire protected by a microcatheter or guide catheter extension.<sup>110,111</sup> To minimize damage to the microcatheter or guide catheter extension by the burr, reposition the catheter between atherectomy runs.
- For bifurcation lesions with calcification of both branches, IVL for discrete calcification allows maintenance of both guide wires. For similarly sized main and side branches, using 1 balloon on both branches may save cost, although it may be challenging to readvance the used IVL balloon on the second wire.

#### Treatment algorithm for calcified CAD

Investigate angiographic evidence of calcification with intravascular imaging to determine the need and optimal method of calcium modification. Predilation with a low-profile balloon may be necessary to facilitate advancement and delivery of the intravascular imaging catheter. Intravascular imaging findings should inform next steps, which may include further predilation with an NC balloon, specialty balloon, atherectomy, and/or IVL.

Established on available evidence, criteria for calcium modification are based on calcium arc, length, and thickness, with recommendations for some form of modification prior to stent deployment for an arc of 360° or an arc of 270° with a calcified length of 2:5.0 mm. Consider calcium modification for CNs within the target segment, small or negatively remodeled vessels, and lesions with a minimum calcium thickness of 2:0.5 mm as assessed by OCT. When deciding on the specific modality to use for calcium modification, consider the length of the calcified segment. Atherectomy may best address long, diffusely calcified lesions, whereas focal lesions may be amenable to treatment with specialty balloons. Consider IVL for concentric, eccentric, and CN lesions and in settings where atherectomy may be relatively contraindicated.

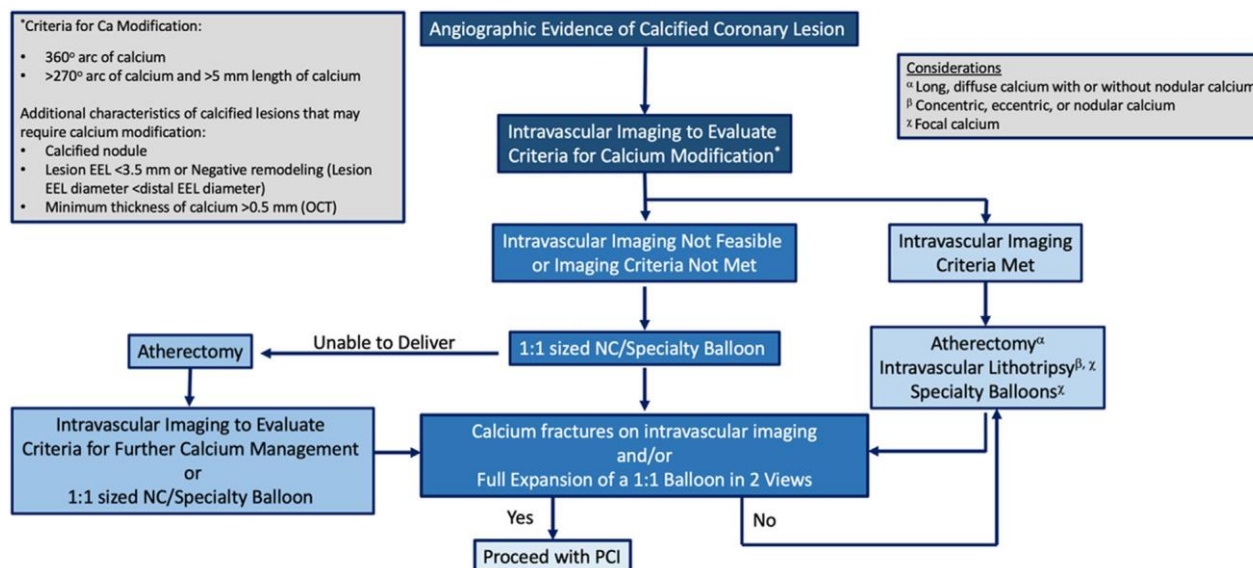


Figure 6.

Treatment algorithm for calcified CAD. Ca, calcium; EEL, external elastic lamina; OCT, optical coherence tomography; NC, noncompliant; PCI, percutaneous coronary intervention. \*Criteria for calcium modification shown on left.

Repeat intravascular imaging to assess for calcium fractures and/or perform a 1:1 sized balloon angioplasty to assess for full expansion in at least 2 views. If these criteria are met, proceed with stent deployment. If, however, the initial form of calcium modification was suboptimal, undertake further intravascular imaging-guided calcium modification therapies prior to stent deployment. Group consensus on the treatment algorithm for calcified CAD is shown in Figure 6.

### Emerging trials and therapies

Several clinical trials are currently investigating the safety and efficacy of these devices in the management of CAC in patients undergoing PCI in both de novo disease and ISR.

The high-pressure OPN balloon is being compared with IVL in the ISAR-CALC 2 (Comparison of Strategies to Prepare Severely Calcified Coronary Lesions; NCT05072730) trial in patients with severely calcified, undilatable coronary lesions who are randomized to either OPN or IVL. The primary outcome will be final angiographic minimal lumen diameter after stent implantation.

The ROTACUT (Rotational atherectomy combined with Cutting balloon to optimize stent expansion in calcified lesions; NCT04865588) trial is a multicenter, randomized pilot study comparing the strategy of RA plus the Wolverine CB vs RA plus plain conventional balloon angioplasty in 60 patients with advanced calcific de novo disease. The trial is evaluating MSA, stent expansion, and stent apposition with IVUS, as well as short-term periprocedural clinical outcomes.

PREPARE-CALC COMBO (Evaluation of a Strategy to Prepare severely Calcified Coronary Lesions with a Combination of rotational atherectomy and Modified Balloons Trial; NCT04014595) is a single-arm prospective study of 110 patients treated with a RA/CB strategy before DES implantation compared with historical patients from the randomized PREPARE-CALC trial treated with specialty balloons (CB or scoring balloon) or RA alone. The PREPARE-CALC COMBO study has 2 primary end points: in-stent acute lumen gain by quantitative angiographic analysis and stent expansion by OCT. ROTA-ISR (Debulking With Rotational Atherectomy Versus Balloon Angioplasty In Patients With In-stent Restenosis; NCT03401203), on the other hand, is a randomized controlled trial (RCT) that will compare debulking of stents using RA with that using conventional balloon angioplasty in patients

with advanced ISR. Although ROTA-ISR is not specifically targeted to calcified lesions, a substantial number of patients may have severe calcium as a cause for stent underexpansion.

The ECLIPSE (Evaluation of Treatment Strategies for Severe Calcified Coronary Arteries: OA vs. Conventional Angioplasty Technique Prior to Implantation of Drug-Eluting Stents; NCT03108456) trial is a multicenter RCT of 2000 patients comparing vessel preparation with OA vs conventional balloon angioplasty prior to stent implantation in severely calcified coronary artery lesions. The primary end point is 1-year TVF, defined as the composite of cardiac death, target vessel-related myocardial infarction, or ischemia-driven target vessel revascularization. There is also an imaging cohort of 250 subjects per arm, with an OCT assessment of acute MSA at the conclusion of the procedure. Another ongoing OA study is CROWN (Calcium Reduction by Orbital Atherectomy in Western Europe; NCT06035783), which is a 100-patient single-arm study to evaluate post-OA MSA by OCT.

Several RCTs evaluating IVL are underway. The Short-Cut (Shockwave Lithoplasty Compared to Cutting Balloon Treatment in Calcified Coronary Disease Trial; NCT06089135) trial aims to randomize 410 patients with calcified lesions to IVL vs CB in 2 cohorts—those prepared with or without RA. The DECALCIFY (Prospective, Randomized, Controlled, Multicenter Study for the Treatment of Calcified Coronary Arteries Lesions With Rotational Atherectomy vs. Intravascular Lithotripsy; NCT04960319) trial will randomize 100 patients to IVL vs RA and assess in-hospital MACE and stent expansion by OCT. The SONAR (Shockwave Balloon or Atherectomy With Rotablation in Calcified Coronary Artery Lesions; NCT05208749) multicenter RCT of 170 patients will randomize to IVL or RA and assess postprocedural myocardial infarction. The BALI (Balloon Lithoplasty for Preparation of Severely Calcified Coronary Lesions Before Stent Implantation; NCT04253171) RCT will compare IVL with the standard of care (which can include plain balloon angioplasty, CB/scoring balloons, and RA) in 200 patients with the primary end point being strategy failure (failed stent delivery, residual stenosis of  $\geq 20\%$ , or TVF). Finally, the VICTORY (Value of IVL Compared to OPN Non-compliant Balloons for Treatment of Refractory Coronary Lesions; NCT05346068) trial is a noninferiority RCT to compare the impact of IVL with that of very high-pressure balloon on final stent expansion assessed by OCT in 280 patients with calcified lesions.

In addition, several multicenter, observational IVL studies are underway. Intravascular Balloon Lithotripsy in Left Main Stem Percutaneous

Coronary Intervention (NCT04319666) aims to follow 50 patients undergoing PCI for intravascular imaging–defined calcified left main disease. EMPOWER CAD (Equity in modifying plaque of women with undertreated calcified CAD; NCT05755711) is a postmarket, multicenter, single-arm observational study to generate real-world clinical evidence associated with IVL in female patients. Other investigator-initiated, real-world registries examining the role of IVL in CAC are ongoing in various countries.

Innovations in the treatment of CAC include a prospective, single-arm study evaluating the device success rate of a T-wave IVL catheter system (Suzhou Zhonghui Medical Technology; NCT05552131) in 190 patients and the ACTIVE study (Safety and Efficacy Study of the SoundBite Crossing System With ACTIVE Wire in Coronary CTOs; NCT03521804) evaluating a novel guide wire (Soundbite Medical Solutions) that can penetrate calcium using pressure pulses characterized by high amplitude, rapid rise time, and short duration.

Few studies compare multiple calcium modification devices. The ROLLING-STONE study (IVL and/or Mechanical Debulking for Severely Calcified Coronary Artery Lesions; NCT05016726) aims to prospectively follow 400 patients undergoing PCI for calcified disease treated with IVL or atherectomy, while the ROLLERCOASTR trial (Rotational Atherectomy, Lithotripsy, or Laser for the Treatment of Calcified Stenosis; NCT04181268) is one of the few randomized studies aimed at enrolling 150 participants undergoing PCI with RA, IVL, or ELCA for calcified disease.

Finally, there are ongoing developments with coronary computed tomography angiography (CCTA) and artificial intelligence to aid with preprocedural planning with calcium modification therapies prior to PCI. The P4 (Precise Procedural and PCI Plan; NCT05253677) trial is an investigator-initiated, multicenter RCT with a noninferiority design that will compare a CCTA-guided PCI strategy with an IVUS-guided PCI strategy. The primary end point will be 1-year MACE rates between CCTA-guided and IVUS-guided PCI strategy.

## Conclusions

PCI of calcified CAD is increasingly common and associated with higher procedural risk and risk of short-term and long-term adverse events. With an expanding toolbox of therapeutic modalities and use of optimal technique, greater procedural success can be achieved with lower risk of complications. This SCAI consensus document recommends the use of intravascular imaging whenever feasible to determine the use of calcium modification techniques and prepare the vessel for optimal stent deployment in calcified CAD. This consensus document furthers SCAI's goal to provide guidance for interventional cardiologists in the identification and treatment of calcified CAD for consistent delivery of high-quality PCI.

## Declaration of competing interest

Robert F. Riley discloses serving on the speaker's bureau and as a consultant for Shockwave Medical. Jimmy L. Kerrigan served on the advisory council and as a speaker for Philips. Emanouil S. Brilakis served as a consultant and speaker and received honoraria from Cardiovascular Systems, Inc. Kevin J. Croce received research support and honoraria and served as a consultant for Cardiovascular Systems, Inc. Darshan Doshi received honoraria from Shockwave Medical. All other authors reported no financial interests.

## Funding sources

This work was not supported by funding agencies in the public, commercial, or not-for-profit sectors.

## References

- Szerlip M, Al-Azizi K, Alasnag M, et al. SCAI publications committee manual of standard operating procedures: 2022 update. *J Soc Cardiovasc Angiogr Interv.* 2022;1(4):100389. <https://doi.org/10.1016/j.jscai.2022.100389>
- Sutton NR, Malhotra R, St. Hilaire C, et al. Molecular mechanisms of vascular health: insights from vascular aging and calcification. *Arterioscler Thromb Vasc Biol.* 2023;43(1):15–29. <https://doi.org/10.1161/ATVBAHA.122.317332>
- McClelland RL, Chung H, Detrano R, Post W, Kronmal RA. Distribution of coronary artery calcium by race, gender, and age: results from the multi-ethnic study of atherosclerosis (MESA). *Circulation.* 2006;113(1):30–37. <https://doi.org/10.1161/CIRCULATIONAHA.105.580696>
- Kronmal RA, McClelland RL, Detrano R, et al. Risk factors for the progression of coronary artery calcification in asymptomatic subjects: results from the multi-ethnic study of atherosclerosis (MESA). *Circulation.* 2007;115(21):2722–2730. <https://doi.org/10.1161/CIRCULATIONAHA.106.674143>
- Chellan B, Sutton NR, Hofmann Bowman MA. S100/RAGE-mediated inflammation and modified cholesterol lipoproteins as mediators of osteoblastic differentiation of vascular smooth muscle cells. *Front Cardiovasc Med.* 2018;5:163. <https://doi.org/10.3389/fcvm.2018.00163>
- Aikawa E, Nahrendorf M, Figueiredo JL, et al. Osteogenesis associates with inflammation in early-stage atherosclerosis evaluated by molecular imaging in vivo. *Circulation.* 2007;116(24):2841–2850. <https://doi.org/10.1161/CIRCULATIONAHA.107.732867>
- Glagov S, Weisenberg E, Zarins CK, Stankunavicius R, Kolettsis GJ. Compensatory enlargement of human atherosclerotic coronary arteries. *N Engl J Med.* 1987;316(22):1371–1375. <https://doi.org/10.1056/NEJM198705283162204>
- Otsuka F, Sakakura K, Yahagi K, Joner M, Virmani R. Has our understanding of calcification in human coronary atherosclerosis progressed? *Arterioscler Thromb Vasc Biol.* 2014;34(4):724–736. <https://doi.org/10.1161/ATVBAHA.113.302642>
- Agatston AS, Janowitz WR, Hildner FJ, Zusmer NR, Viamonte M, Detrano R. Quantification of coronary artery calcium using ultrafast computed tomography. *J Am Coll Cardiol.* 1990;15(4):827–832. [https://doi.org/10.1016/0735-1097\(90\)90282-T](https://doi.org/10.1016/0735-1097(90)90282-T)
- Choi DY, Hayes D, Maidman SD, et al. Existing nongated CT coronary calcium predicts operative risk in patients undergoing noncardiac surgeries (ENCORES). *Circulation.* 2023;148(15):1154–1164. <https://doi.org/10.1161/CIRCULATIONAHA.123.064398>
- Wang X, Matsumura M, Mintz GS, et al. In vivo calcium detection by comparing optical coherence tomography, intravascular ultrasound, and angiography. *J Am Coll Cardiol Cardiovasc Imaging.* 2017;10(8):869–879. <https://doi.org/10.1016/j.jcmg.2017.05.014>
- Mintz GS, Popma JJ, Pichard AD, et al. Patterns of calcification in coronary artery disease: a statistical analysis of intravascular ultrasound and coronary angiography in 1155 lesions. *Circulation.* 1995;91(7):1959–1965. <https://doi.org/10.1161/01.CIR.91.7.1959>
- Lee JM, Choi KH, Song YB, et al. Intravascular imaging–guided or angiography–guided complex PCI. *N Engl J Med.* 2023;388(18):1668–1679. <https://doi.org/10.1056/NEJMoa2216607>
- Buccheri S, Franchina G, Romano S, et al. Clinical outcomes following intravascular imaging–guided versus coronary angiography–guided percutaneous coronary intervention with stent implantation. *J Am Coll Cardiol Interv.* 2017;10(24):2488–2498. <https://doi.org/10.1016/j.jcin.2017.08.051>
- Lawton JS, Tamis-Holland JE, Bangalore S, et al. 2021 ACC/AHA/SCAI guideline for coronary artery revascularization. *J Am Coll Cardiol.* 2022;79(2):e121–e129. <https://doi.org/10.1016/j.jacc.2021.09.006>
- Friedrich GJ, Moes NY, Mühlberger VA, et al. Detection of intralumenal calcium by intracoronary ultrasound depends on the histologic pattern. *Am Heart J.* 1994;128(3):435–441. [https://doi.org/10.1016/0002-8703\(94\)90614-9](https://doi.org/10.1016/0002-8703(94)90614-9)
- Kume T, Okura H, Kawamoto T, et al. Assessment of the coronary calcification by optical coherence tomography. *EuroIntervention.* 2011;6(6):768–772. <https://doi.org/10.4244/EIJV6I6A130>
- Zhang M, Matsumura M, Usui E, et al. Intravascular ultrasound–derived calcium score to predict stent expansion in severely calcified lesions. *Circ Cardiovasc Interv.* 2021;14(10). <https://doi.org/10.1161/CIRCINTERVENTIONS.120.010296>
- Fujino A, Mintz GS, Matsumura M, et al. A new optical coherence tomography–based calcium scoring system to predict stent underexpansion. *EuroIntervention.* 2018;13(18):2182–2189. <https://doi.org/10.4244/EIJ-D-17-00962>
- Maejima N, Hibi K, Saka K, et al. Relationship between thickness of calcium on optical coherence tomography and crack formation after balloon dilatation in calcified plaque requiring rotational atherectomy. *Circ J.* 2016;80(6):1413–1419. <https://doi.org/10.1253/circj.CJ-15-1059>
- Fujino A, Mintz GS, Lee T, et al. Predictors of calcium fracture derived from balloon angioplasty and its effect on stent expansion assessed by optical coherence tomography. *J Am Coll Cardiol Interv.* 2018;11(10):1015–1017. <https://doi.org/10.1016/j.jcin.2018.02.004>
- Kurata N, Ishihara T, Iida O, et al. Predictors for calcium fracture with a novel cutting balloon: an optical coherence tomography study. *J Am Coll Cardiol Interv.* 2022;15(8):904–906. <https://doi.org/10.1016/j.jcin.2022.02.017>
- Lee T, Mintz GS, Matsumura M, et al. Prevalence, predictors, and clinical presentation of a calcified nodule as assessed by optical coherence

- tomography. *J Am Coll Cardiol Cardiovasc Img*. 2017;10(8):883–891. <https://doi.org/10.1016/j.jcmg.2017.05.013>
24. Sato T, Matsumura M, Yamamoto K, et al. Impact of eruptive vs noneruptive calcified nodule morphology on acute and long-term outcomes after stenting. *J Am Coll Cardiol Interv*. 2023;16(9):1024–1035. <https://doi.org/10.1016/j.jcin.2023.03.009>
  25. Lee JB, Mintz GS, Lisauskas JB, et al. Histopathologic validation of the intravascular ultrasound diagnosis of calcified coronary artery nodules. *Am J Cardiol*. 2011;108(11):1547–1551. <https://doi.org/10.1016/j.amjcard.2011.07.014>
  26. Torii S, Sato Y, Otsuka F, et al. Eruptive calcified nodules as a potential mechanism of acute coronary thrombosis and sudden death. *J Am Coll Cardiol*. 2021;77(13):1599–1611. <https://doi.org/10.1016/j.jacc.2021.02.016>
  27. Sato T, Yamamoto K, Matsumura M, et al. Discrimination of calcified nodule as a cause of coronary angiographic radiolucent mass. *J Am Coll Cardiol Interv*. 2023;16(15):1948–1949. <https://doi.org/10.1016/j.jcin.2023.04.013>
  28. Morofuji T, Kuramitsu S, Shinozaki T, et al. Clinical impact of calcified nodule in patients with heavily calcified lesions requiring rotational atherectomy. *Catheter Cardiovasc Interv*. 2021;97(1):10–19. <https://doi.org/10.1002/ccd.28896>
  29. Tada T, Miura K, Ikuta A, et al. Prevalence, predictors, and outcomes of in-stent restenosis with calcified nodules. *EuroIntervention*. 2022;17(16):1352–1361. <https://doi.org/10.4244/EIJ-D-21-00504>
  30. Morino Y, Abe M, Morimoto T, et al. Predicting successful guidewire crossing through chronic total occlusion of native coronary lesions within 30 minutes. *J Am Coll Cardiol Interv*. 2011;4(2):213–221. <https://doi.org/10.1016/j.jcin.2010.09.024>
  31. Ryan TJ, Faxon DP, Gunnar RM, et al. Guidelines for percutaneous transluminal coronary angioplasty. A report of the American College of Cardiology/American Heart Association Task Force on Assessment of Diagnostic and Therapeutic Cardiovascular Procedures (Subcommittee on Percutaneous Transluminal Coronary Angioplasty). *Circulation*. 1988;78(2):486–502. <https://doi.org/10.1161/01.CIR.78.2.486>
  32. Szigyarto Z, Rampat R, Werner GS, et al. Derivation and validation of a chronic total coronary occlusion intervention procedural success score from the 20,000-Patient EuroCTO Registry: the EuroCTO (CASTLE) score. *J Am Coll Cardiol Interv*. 2019;12(4):335–342. <https://doi.org/10.1016/j.jcin.2018.11.020>
  33. Maeremans J, Spratt JC, Knaepen P, et al. Towards a contemporary, comprehensive scoring system for determining technical outcomes of hybrid percutaneous chronic total occlusion treatment: the RECHARGE score. *Catheter Cardiovasc Interv*. 2018;91(2):192–202. <https://doi.org/10.1002/ccd.27092>
  34. Simsek B, Kostantini S, Karacsonyi J, et al. Predicting periprocedural complications in chronic total occlusion percutaneous coronary intervention: the PROGRESS-CTO complication scores. *J Am Coll Cardiol Interv*. 2022;15(14):1413–1422. <https://doi.org/10.1016/j.jcin.2022.06.007>
  35. Ito T, Tsuchikane E, Nasu K, et al. Impact of lesion morphology on angiographic and clinical outcomes in patients with chronic total occlusion after recanalization with drug-eluting stents: a multislice computed tomography study. *Eur Radiol*. 2015;25(10):3084–3092. <https://doi.org/10.1007/s00330-015-3706-3>
  36. Galassi AR, Sumitsuji S, Boukhris M, et al. Utility of intravascular ultrasound in percutaneous revascularization of chronic total occlusions. *J Am Coll Cardiol Interv*. 2016;9(19):1979–1991. <https://doi.org/10.1016/j.jcin.2016.06.057>
  37. Dangas GD, Claessen BE, Caixeta A, Sanidas EA, Mintz GS, Mehran R. In-stent restenosis in the drug-eluting stent era. *J Am Coll Cardiol*. 2010;56(23):1897–1907. <https://doi.org/10.1016/j.jacc.2010.07.028>
  38. Alfonso F, Sandoval J, Nolte C. Calcified in-stent restenosis: a rare cause of dilation failure requiring rotational atherectomy. *Circ Cardiovasc Interv*. 2012;5(1). <https://doi.org/10.1161/CIRCINTERVENTIONS.111.966606>
  39. Nakamura N, Torii S, Tsuchiya H, et al. Formation of calcified nodule as a cause of early in-stent restenosis in patients undergoing dialysis. *J Am Heart Assoc*. 2020;9(19):e016595. <https://doi.org/10.1161/JAHA.120.016595>
  40. Chen Z, Matsumura M, Mintz GS, et al. Prevalence and impact of neoatherosclerosis on clinical outcomes after percutaneous treatment of second-generation drug-eluting stent restenosis. *Circ Cardiovasc Interv*. 2022;15(9):e011693. <https://doi.org/10.1161/CIRCINTERVENTIONS.121.011693>
  41. Yin D, Mintz GS, Song L, et al. In-stent restenosis characteristics and repeat stenting underexpansion: insights from optical coherence tomography. *EuroIntervention J Eur Collab Work Group Interv Cardiol Eur Soc Cardiol*. 2020;16(4):e335–e343. <https://doi.org/10.4244/EIJ-D-18-01191>
  42. Kawashima H, Serruys PW, Hara H, et al. 10-year all-cause mortality following percutaneous or surgical revascularization in patients with heavy calcification. *J Am Coll Cardiol Interv*. 2022;15(2):193–204. <https://doi.org/10.1016/j.jcin.2021.10.026>
  43. Abazid RM, Romsa JG, Akincioglu C, et al. Coronary artery calcium progression after coronary artery bypass grafting surgery. *Open Heart*. 2021;8(1):e001684. <https://doi.org/10.1136/openhrt-2021-001684>
  44. Cashin WL, Sanmarco ME, Nessim SA, Blankenhorn DH. Accelerated progression of atherosclerosis in coronary vessels with minimal lesions that are bypassed. *N Engl J Med*. 1984;311(13):824–828. <https://doi.org/10.1056/NEJM198409273111304>
  45. Kwicinski J, Tzolos E, Fletcher AJ, et al. Bypass grafting and native coronary artery disease activity. *J Am Coll Cardiol Cardiovasc Img*. 2022;15(5):875–887. <https://doi.org/10.1016/j.jcmg.2021.11.030>
  46. Kroncke GM, Kosolcharoen P, Clayton JA, Peduzzi PN, Detre K, Takaro T. Five-year changes in coronary arteries of medical and surgical patients of the Veterans Administration Randomized Study of Bypass Surgery. *Circulation*. 1988;78(3 Pt 2):144–150.
  47. Wolny R, Mintz GS, Matsumura M, et al. Left coronary artery calcification patterns after coronary bypass graft surgery: an in-vivo optical coherence tomography study. *Catheter Cardiovasc Interv*. 2021;98(3):483–491. <https://doi.org/10.1002/ccd.29220>
  48. Shang Y, Mintz GS, Pu J, et al. Bypass to the left coronary artery system may accelerate left main coronary artery negative remodeling and calcification. *Clin Res Cardiol*. 2013;102(11):831–835. <https://doi.org/10.1007/s00392-013-0598-6>
  49. Ge ne reux P, Madhavan MV, Mintz GS, et al. Ischemic outcomes after coronary intervention of calcified vessels in acute coronary syndromes. *J Am Coll Cardiol*. 2014;63(18):1845–1854. <https://doi.org/10.1016/j.jacc.2014.01.034>
  50. Tanigawa J, Barlis P, Mario CD. Heavily calcified coronary lesions preclude strut apposition despite high pressure balloon dilatation and rotational atherectomy in-vivo demonstration with optical coherence tomography: in-vivo demonstration with optical coherence tomography. *Circ J*. 2008;72(1):157–160. <https://doi.org/10.1253/circj.72.157>
  51. Wiemer M, Butz T, Schmidt W, Schmitz KP, Horstkotte D, Langer C. Scanning electron microscopic analysis of different drug eluting stents after failed implantation: from nearly undamaged to major damaged polymers. *Catheter Cardiovasc Interv*. 2010;75(6):905–911. <https://doi.org/10.1002/ccd.22347>
  52. Moussa I, Ellis SG, Jones M, et al. Impact of coronary culprit lesion calcium in patients undergoing paclitaxel-eluting stent implantation (a TAXUS-IV sub study). *Am J Cardiol*. 2005;96(9):1242–1247. <https://doi.org/10.1016/j.amjcard.2005.06.064>
  53. Truesdell AG, Khuddus MA, Martinez SC, Shlofmitz E. Calcified lesion assessment and intervention in complex percutaneous coronary intervention: overview of angioplasty, atherectomy, and lithotripsy. *US Cardiol Rev*. 2020;14:e05. <https://doi.org/10.15420/usc.2020.16>
  54. Shah M, Najam O, Bhandi R, De Silva K. Calcium modification techniques in complex percutaneous coronary intervention. *Circ Cardiovasc Interv*. 2021;14(5):e009870. <https://doi.org/10.1161/CIRCINTERVENTIONS.120.009870>
  55. Albiero R, Silber S, Di Mario C, et al. Cutting balloon versus conventional balloon angioplasty for the treatment of in-stent restenosis. *J Am Coll Cardiol*. 2004;43(6):943–949. <https://doi.org/10.1016/j.jacc.2003.09.054>
  56. Mangieri A, Nerla R, Castriota F, et al. Cutting balloon to optimize predilatation for stent implantation: the COPS randomized trial. *Catheter Cardiovasc Interv*. 2023;101(4):798–805. <https://doi.org/10.1002/ccd.30603>
  57. Ishihara T, Iida O, Takahara M, et al. Improved crossability with novel cutting balloon versus scoring balloon in the treatment of calcified lesion. *Cardiovasc Interv Ther*. 2021;36(2):198–207. <https://doi.org/10.1007/s12928-020-00663-5>
  58. Secco GG, Buettnner A, Parisi R, et al. Clinical experience with very high-pressure dilatation for resistant coronary lesions. *Cardiovasc Revasc Med*. 2019;20(12):1083–1087. <https://doi.org/10.1016/j.carrev.2019.02.026>
  59. Senguttuvan NB, Singh H, Kumar BV, et al. Safety and efficacy of OPN balloon in patients with calcified coronary artery disease. *Cardiovasc Revasc Med*. 2023;54:25–30. <https://doi.org/10.1016/j.carrev.2023.02.018>
  60. Ahn SS, Auth D, Marcus DR, Moore WS. Removal of focal atheromatous lesions by angioscopically guided high-speed rotary atherectomy. *J Vasc Surg*. 1988;7(2):292–300. <https://doi.org/10.1067/mva.1988.avs0070292>
  61. Abdel-Wahab M, Richardt G, Joachim Büttner H, et al. High-speed rotational atherectomy before paclitaxel-eluting stent implantation in complex calcified coronary lesions. *J Am Coll Cardiol Interv*. 2013;6(1):10–19. <https://doi.org/10.1016/j.jcin.2012.07.017>
  62. Abdel-Wahab M, Toelg R, Byrne RA, et al. High-speed rotational atherectomy versus modified balloons prior to drug-eluting stent implantation in severely calcified coronary lesions: the randomized PREPARE-CALC trial. *Circ Cardiovasc Interv*. 2018;11(10):e007415. <https://doi.org/10.1161/CIRCINTERVENTIONS.118.007415>
  63. Whiteside HL, Ratanapo S, Sey A, Omar A, Kapoor D. Efficacy of a heparin based rota-flush solution in patients undergoing rotational atherectomy. *Cardiovasc Revasc Med*. 2018;19(3):333–337. <https://doi.org/10.1016/j.carrev.2017.08.013>
  64. Lee MS, Kim MH, Rha SW. Alternative rota-flush solution for patients with severe coronary artery calcification who undergo rotational atherectomy. *J Invasive Cardiol*. 2017;29(1):25–28.
  65. Guo Z, Hu H, Hua J, Ma L. Comparison of two different Rota-flush solutions in patients undergoing rotational atherectomy: a randomized, controlled, triple-blind trial. *Cardiol Ther*. 2022;11(4):531–543. <https://doi.org/10.1007/s40119-022-00279-1>
  66. Lai CH, Su CS, Wang CY, Lee WL. Heavily calcified plaques in acutely angulated coronary segment: high risk features of rotablation resulting in Rotawire transection and coronary perforation. *Int J Cardiol*. 2015;182:112–114. <https://doi.org/10.1016/j.ijcard.2014.12.119>
  67. Megaly M, Sandoval Y, Lillyblad MP, Brilakis ES. Aminophylline for preventing bradyarrhythmias during orbital or rotational atherectomy of the right coronary artery. *J Invasive Cardiol*. 2018;30(5):186–189.
  68. Parikh K, Chandra P, Choksi N, Khanna P, Chambers J. Safety and feasibility of orbital atherectomy for the treatment of calcified coronary lesions: the ORBIT I trial. *Catheter Cardiovasc Interv*. 2013;81(7):1134–1139. <https://doi.org/10.1002/ccd.24700>
  69. Chambers JW, Feldman RL, Himmelstein SI, et al. Pivotal trial to evaluate the safety and efficacy of the orbital atherectomy system in treating de novo, severely calcified coronary lesions (ORBIT II). *J Am Coll Cardiol Interv*. 2014;7(5):510–518. <https://doi.org/10.1016/j.jcin.2014.01.158>

70. Goel S, Pasam RT, Chava S, et al. Orbital atherectomy versus rotational atherectomy: a systematic review and meta-analysis. *Int J Cardiol.* 2020;303:16–21. <https://doi.org/10.1016/j.ijcard.2019.12.037>
71. Lee MS, Shlofmitz E, Kong J, et al. Outcomes of patients with severely calcified aorto-ostial coronary lesions who underwent orbital atherectomy. *J Intervent Cardiol.* 2018;31(1):15–20. <https://doi.org/10.1111/joic.12432>
72. Reifart N, Vandormael M, Krajcar M, et al. Randomized comparison of angioplasty of complex coronary lesions at a single center: excimer laser, rotational atherectomy, and balloon angioplasty comparison (ERBAC) study. *Circulation.* 1997;96(1):91–98. <https://doi.org/10.1161/01.CIR.96.1.91>
73. Ebersole D, Dahm JB, Das T, et al. Excimer laser revascularization of saphenous vein grafts in acute myocardial infarction. *J Invasive Cardiol.* 2004;16(4):177–180.
74. Bittl JA, Sanborn TA, Yardley DE, et al. Predictors of outcome of percutaneous excimer laser coronary angioplasty of saphenous vein bypass graft lesions. *Am J Cardiol.* 1994;74(2):144–148. [https://doi.org/10.1016/0002-9149\(94\)90087-6](https://doi.org/10.1016/0002-9149(94)90087-6)
75. Lee T, Shlofmitz RA, Song L, et al. The effectiveness of excimer laser angioplasty to treat coronary in-stent restenosis with peri-stent calcium as assessed by optical coherence tomography. *EuroIntervention.* 2019;15(3):e279–e288. <https://doi.org/10.4244/EIJ-D-18-00139>
76. Bansal A, Gupta S, Jain V, et al. Adverse events related to excimer laser coronary atherectomy: analysis of the FDA MAUDE database. *Cardiovasc Revasc Med.* 2021;27:88–89. <https://doi.org/10.1016/j.carrev.2020.12.024>
77. Hill JM, Kereiakes DJ, Shlofmitz RA, et al. Intravascular lithotripsy for treatment of severely calcified coronary artery disease. *J Am Coll Cardiol.* 2020;76(22):2635–2646. <https://doi.org/10.1016/j.jacc.2020.09.603>
78. Kereiakes DJ, Hill JM, Shlofmitz RA, et al. Intravascular lithotripsy for treatment of severely calcified coronary lesions: 1-year results from the disrupt CAD III study. *J Soc Cardiovasc Angiogr Interv.* 2022;1(1):100001. <https://doi.org/10.1016/j.jscv.2021.100001>
79. Kereiakes DJ, Di Mario C, Riley RF, et al. Intravascular lithotripsy for treatment of calcified coronary lesions: patient-level pooled analysis of the disrupt CAD studies. *J Am Coll Cardiol Interv.* 2021;14(12):1337–1348. <https://doi.org/10.1016/j.jcin.2021.04.015>
80. Ali ZA, Kereiakes DJ, Hill JM, et al. Impact of calcium eccentricity on the safety and effectiveness of coronary intravascular lithotripsy: pooled analysis from the disrupt CAD studies. *Circ Cardiovasc Interv.* 2023;16(10):e012898. <https://doi.org/10.1161/CIRCINTERVENTIONS.123.012898>
81. Ali ZA, Kereiakes D, Hill J, et al. Safety and effectiveness of coronary intravascular lithotripsy for treatment of calcified nodules. *J Am Coll Cardiol Interv.* 2023;16(9):1122–1124. <https://doi.org/10.1016/j.jcin.2023.02.015>
82. Riley RF, Miller LE, Davies R, et al. Retrospective multicenter analysis of intravascular lithotripsy use during calcified left main coronary artery percutaneous coronary interventions. *J Soc Cardiovasc Angiogr Interv.* Published online November 10, 2023. <https://doi.org/10.1016/j.jscv.2023.10.1213>
83. Nikolakopoulos I, Vemmo E, Xenogiannis I, Brilakis ES. Combined use of intravascular lithotripsy and brachytherapy: a new approach for the treatment of recurrent coronary in-stent restenosis. *Catheter Cardiovasc Interv.* 2021;97(7):1402–1406. <https://doi.org/10.1002/ccd.29332>
84. Kassab K, Kassier A, Fischell TA. Intracoronary lithotripsy use for in-stent restenosis, including multilayer ISR. *Cardiovasc Revasc Med.* 2022;44:10–13. <https://doi.org/10.1016/j.carrev.2022.06.261>
85. Aksoy A, Salazar C, Becher MU, et al. Intravascular lithotripsy in calcified coronary lesions: a prospective, observational, multicenter registry. *Circ Cardiovasc Interv.* 2019;12(11):e008154. <https://doi.org/10.1161/CIRCINTERVENTIONS.119.008154>
86. Rao RS, Sharma GN, Kunal S, Garhwal K, Bajiya S, Mehta P. Safety and procedural outcomes of intravascular lithotripsy in calcified coronaries in Indian patients. *Indian Heart J.* 2022;74(2):91–95. <https://doi.org/10.1016/j.ihj.2022.01.001>
87. Lee TJ, Wan Rahimi WFB, Low MY, Nurrudin AA. Type E coronary artery dissection caused by intravascular lithotripsy balloon rupture; vessel anatomy and characteristics in a lithoplasty complication case as detailed by optical coherence tomography: a case report. *Eur Heart J Case Rep.* 2021;5(12):ytb432. <https://doi.org/10.1093/ehjcr/ytb432>
88. Wong B, Kam KKH, So CY, et al. Synergistic coronary artery calcium modification with combined atherectomy and intravascular lithotripsy. *J Invasive Cardiol.* 2023;35(3):E128–E135.
89. Pengchata P, Pongakasira R, Wongsawangkit N, Pichaphop A, Wongprapart N. Characteristics and pattern of calcified nodule and/or nodular calcification detected by intravascular ultrasound on the device-oriented composite endpoint (DoCE) in patients with heavily calcified lesions who underwent rotational atherectomy-assisted percutaneous coronary intervention. *J Intervent Cardiol.* 2023;2023:6456695. <https://doi.org/10.1155/2023/6456695>
90. Watanabe Y, Sakakura K, Taniguchi Y, et al. Comparison of clinical outcomes of intravascular ultrasound-calcified nodule between percutaneous coronary intervention with versus without rotational atherectomy in a propensity-score matched analysis. *PLoS One.* 2020;15(11):e0241836. <https://doi.org/10.1371/journal.pone.0241836>
91. Abellas-Sequeiros M, Sanchez-Recalde A, Pardo-Sanz A, Salido-Tahoces, And L, Luis Zamorano J. Orbital atherectomy for calcified nodule: optical coherence tomography assessment. *REC Interv Cardiol.* Published online May 10, 2022. <https://doi.org/10.24875/RECICE.M21000256>
92. Oka T, Sanada R, Urabe Y, Mitsuba N, Fukuda Y, Ueda H. Effectiveness of using both rotational atherectomy with smallest burr and orbital atherectomy system for stentless treatment of calcified nodules. *Cardiovasc Interv Ther.* 2023;38(4):424–426. <https://doi.org/10.1007/s12928-023-00931-0>
93. Xenogiannis I, Karpaliotis D, Alaswad K, et al. Usefulness of atherectomy in chronic total occlusion interventions (from the PROGRESS-CTO Registry). *Am J Cardiol.* 2019;123(9):1422–1428. <https://doi.org/10.1016/j.amjcard.2019.01.054>
94. Kostantinis S, Simsek B, Karacsonyi J, et al. Intravascular lithotripsy in chronic total occlusion percutaneous coronary intervention: insights from the PROGRESS-CTO registry. *Catheter Cardiovasc Interv.* 2022;100(4):512–519. <https://doi.org/10.1002/ccd.30354>
95. Fernandez JP, Hobson AR, McKenzie D, et al. Beyond the balloon: excimer coronary laser atherectomy used alone or in combination with rotational atherectomy in the treatment of chronic total occlusions, non-crossable and non-expandable coronary lesions. *EuroIntervention.* 2013;9(2):243–250. <https://doi.org/10.4244/EIJV9I2A40>
96. Capretti G, Carlino M, Colombo A, Azzalini L. Rotational atherectomy in the subadventitial space to allow safe and successful chronic total occlusion recanalization: pushing the limit further. *Catheter Cardiovasc Interv.* 2018;91(1):47–52. <https://doi.org/10.1002/ccd.27035>
97. Ribeiro MH, Dallan LAP, Quesada FH, et al. Extra-plaque rotational atherectomy for treating a balloon uncrossable ostial right coronary artery chronic total occlusion. *Cardiovasc Revasc Med.* Published online June 5, 2023. <https://doi.org/10.1016/j.carrev.2023.06.002>
98. vom Dahl J, Dietz U, Haager PK, et al. Rotational atherectomy does not reduce recurrent in-stent restenosis: results of the angioplasty versus rotational atherectomy for treatment of diffuse in-stent restenosis trial (ARTIST). *Circulation.* 2002;105(5):583–588. <https://doi.org/10.1161/hc0502.103347>
99. Eged M. A novel approach for under-expanded stent: excimer laser in contrast medium. *J Invasive Cardiol.* 2012;24(8):E161–E163.
100. Sharma SK, Duvvuri S, Dargas G, et al. Rotational atherectomy for in-stent restenosis: acute and long-term results of the first 100 cases. *J Am Coll Cardiol.* 1998;32(5):1358–1365. [https://doi.org/10.1016/s0735-1097\(98\)00382-9](https://doi.org/10.1016/s0735-1097(98)00382-9)
101. Neupane S, Basir M, Tan C, et al. Feasibility and safety of orbital atherectomy for the treatment of in-stent restenosis secondary to stent under-expansion. *Catheter Cardiovasc Interv.* 2021;97(1):2–7. <https://doi.org/10.1002/ccd.28675>
102. Klein LW, Nathan S, Maehara A, et al. SCAI expert consensus statement on management of in-stent restenosis and stent thrombosis. *J Soc Cardiovasc Angiogr Interv.* 2023;2(4), 100971. <https://doi.org/10.1016/j.jscv.2023.100971>
103. Levi Y, Kobo O, Halabi M, et al. Treatment of ostial right coronary artery narrowings: outcomes from the multicenter prospective e-ULTIMASTER registry. *J Soc Cardiovasc Angiogr Interv.* 2023;2(3):100604. <https://doi.org/10.1016/j.jscv.2023.100604>
104. Yamamoto K, Sato T, Salem H, et al. Mechanisms and treatment outcomes of ostial right coronary artery in-stent restenosis. *EuroIntervention.* 2023;19(5):e383–e393. <https://doi.org/10.4244/EIJ-D-23-00107>
105. Chambers JW, Martinsen BJ, Sturm RC, et al. Orbital atherectomy of calcified coronary ostial lesions. *Catheter Cardiovasc Interv.* 2022;100(4):553–559. <https://doi.org/10.1002/ccd.30369>
106. Motwani JG, Raymond RE, Franco I, Ellis SG, Whitlow PL. Effectiveness of rotational atherectomy of right coronary artery ostial stenosis. *Am J Cardiol.* 2000;85(5):563–567. [https://doi.org/10.1016/s0002-9149\(99\)00812-7](https://doi.org/10.1016/s0002-9149(99)00812-7)
107. Chambers JW, Warner C, Cortez J, Behrens AN, Wrede DT, Martinsen BJ. Outcomes after atherectomy treatment of severely calcified coronary bifurcation lesions: a single center experience. *Cardiovasc Revasc Med.* 2019;20(7):569–572. <https://doi.org/10.1016/j.carrev.2018.08.017>
108. Allali A, Abdel-Wahab M, Traboulsi H, et al. Impact of lesion preparation technique on side branch compromise in calcified coronary bifurcations: a subgroup analysis of the PREPARE-CALC trial. *J Intervent Cardiol.* 2020;2020:9740938. <https://doi.org/10.1155/2020/9740938>
109. Sturm R, Armstrong EJ, Benhuri B, et al. Orbital atherectomy for treatment of severely calcified coronary artery bifurcation lesions: a multicenter analysis. *Cardiovasc Revasc Med.* 2021;26:34–38. <https://doi.org/10.1016/j.carrev.2020.10.023>
110. Bangalore S, Koshi L, Keller N, Thompson C. Protected rotational atherectomy and DK NanoCrush POT rePOT technique with dual guiding catheters for unprotected distal left main. *J Am Coll Cardiol Interv.* 2020;13(21):e191–e193. <https://doi.org/10.1016/j.jcin.2020.08.019>
111. Hafiz AM, Smith C, Kakouros N. The GuideLiner-sleeve technique: a novel technique for high-risk PCI using two left main guides for orbital atherectomy of two-vessel calcified ostial coronary artery disease. *J Invasive Cardiol.* 2017;29(11):E159–E160.