

Intravascular lithotripsy: Not an eccentric option for eccentric calcium

Severe coronary artery calcification presents a major obstacle for percutaneous coronary intervention (PCI), increasing the likelihood of complications such as impaired stent expansion and limited lesion crossing. Eccentric calcified lesions, whereby plaque volume is more concentrated on one side of the vessel, provides a further layer of complication. The challenge of treating eccentric coronary calcification is well known, and established technologies such as balloon angioplasty, cutting or scoring balloons, and atherectomy suffer limitations when faced with the presence of eccentric plaque.

Coronary intravascular lithotripsy (IVL, Shockwave Medical) offers an alternative method for the treatment of eccentric calcium. IVL uses sonic pressure waves, known as shockwaves, that pass through soft arterial tissue and preferentially disrupt calcified plaque by creating a series of microfractures. Carlo Di Mario (Careggi University Hospital, Florence, Italy) and Holger Nef (Giessen University Hospital, Giessen, Germany) have experience of the use of IVL in eccentric coronary lesions, and believe that the technology has the potential to bring about consistent improvements in procedural and clinical outcomes when deployed in this challenging subset of lesions. The pair spoke to *Cardiovascular News* about the challenges of treating eccentric lesions, and offer their experience of having used IVL in these complex cases.



Carlo Di Mario

“A common belief is that when the calcium arc is less than 180 degrees you can achieve a normal expansion stretching the opposite wall—but, this is only partially true,” says Di Mario, outlining why interventional cardiologists should pay particular attention to the challenge posed by eccentric calcification. Nef adds that due to the eccentricity of calcified lesions, high pressure balloon dilatation often results in disruption or dissection of healthy intima or

fibrous plaques rather than modification of calcified segments within the artery.

“When you have a very thick eccentric calcium plate, fracturing the calcium with balloons on their own is very difficult,” says Di Mario. “If you do not break the calcium the shape of the final lumen after stenting will be oval or kidney-shaped and struts will have unavoidable major malapposition—two abnormalities that are only partially correctable with in-stent final postdilatation, no matter how large the balloon and high the pressure.”

Using IVL in eccentric coronary calcification

Di Mario explains that in most cases only predilatation is used, adjusting the pressure of the balloon expansion if the operator is skilled enough to monitor expansion in a view perpendicular to the calcified eccentric lesion. Cutting or scoring balloons may be considered, Di Mario adds, but comments that they are potentially dangerous if the opposite, non-calcified wall has limited or no plaque.

Rotational or orbital atherectomy is often reserved for lesions that are uncrossable or undilatable, Di Mario explains, commenting that the principle of differential cutting means the non-calcified wall is spared during activation, “except in tortuous anatomies with sharp bends and prominent wire bias”. He comments that the main limitation of this approach, however, is a relative inefficiency to ablate calcium unless the initial minimal lumen of the lesion is very small or the wire



Holger Nef

bias is favourable to push the burr in contact with calcium.

Nef adds that although cutting and scoring balloons are able to debulk lesions more intensely than non-compliant (NC) balloons, they suffer from the same limitation. “Even rotational or orbital atherectomy, the most effective techniques for modification of calcified plaques available prior to IVL, are limited due to guidewire bias, that may result in inhomogeneous ablation leaving significant areas of the calcified plaques unmodified, particularly in eccentric lesions,” he suggests.

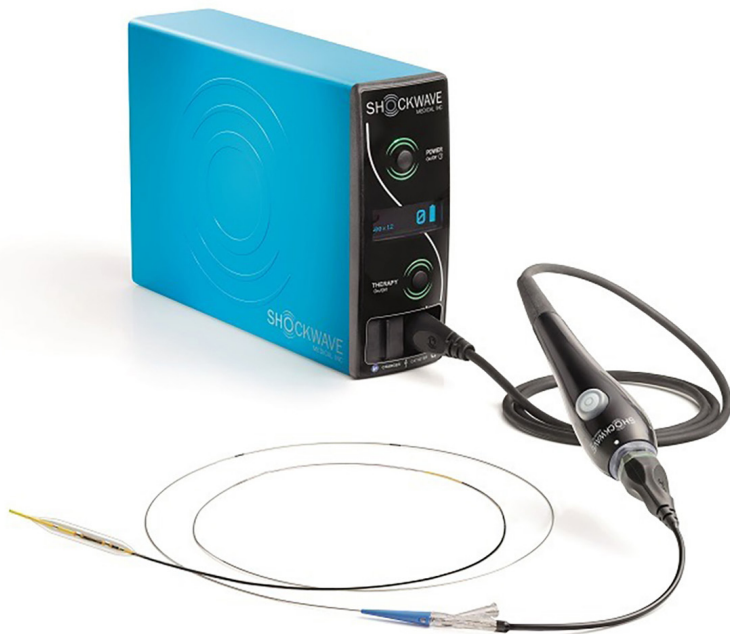This is where IVL becomes an option. Di Mario comments: “Theoretically, IVL does not suffer the limitations of rotational or orbital atherectomy.” He notes that if a balloon large enough to match the reference diameter has been selected it should be in contact with the calcified plate promoting the development of microfractures.

Whilst Di Mario describes the technology as “sophisticated”, creating rapidly expanding vapour bubbles within the balloon that result in acoustic shockwaves that hit the calcium with ~50atm of pressure, for the operator it is no different to the delivery of a conventional balloon, he comments.

Adds Nef: “IVL catheters are equipped with lithotripsy emitters that deliver localised pulsatile acoustic pressure waves circumferentially to modify vascular calcium. This provides the unique opportunity to modify the calcified plaque homogeneously and reach calcification even in deeper vessel layers. Since the IVL works as a rapid exchange system—like a normal angioplasty balloon catheter—the ease of use is obvious.”

Safety and efficacy

The effectiveness and safety of IVL in eccentric calcified coronary lesions has been studied via a patient-level pooled analysis from the DISRUPT CAD I and II studies, findings of which were recently published in *Clinical Research in Cardiology*. Authored by Nef and colleagues the study gathered data from 47 patients with eccentric lesions, which was defined as having one of its luminal edges



in the outer quarter of the apparently normal vessel lumen. These patients were compared to 133 patients with concentric lesions. In the study, Nef and colleagues reported a similar level of clinical success with IVL in both the eccentric lesions and concentric lesions, defined as residual stenosis <50% after stenting with no in-hospital major adverse cardiac events (MACE), (93.6% vs. 93.2%, p=1).

The study reports similar final acute gain and percentage of residual stenosis in both eccentric and concentric cohorts. Final residual stenosis of 8.6±9.8% in the eccentric and 10±9% (p=0.56) in concentric stenosis, while the final minimum stent diameter was significantly greater in eccentric versus concentric lesions (3±0.5 vs. 2.7±0.5mm, p=0.004).

Rates of flow-limiting dissections reported in the study (Grade D–F) were 0% eccentric, and 1.7% concentric (p=0.54). Nef comments: “From a safety perspective, there were no perforations, abrupt closure, slow flow or no reflow events observed in either group, and there were low rates of flow-limiting dissections.”

Di Mario emphasises that safety is the main advantage of IVL—with no perforations or no-reflow post-IVL confirmed in both eccentric and concentric lesions during the study.

A further consideration in the treatment of eccentric calcification is the use of imaging technology to optimise the IVL, which Di Mario suggests is an important aspect. “Without intravascular imaging the attribution of a calcific lesion to the eccentric group is purely speculative since only intravascular ultrasound (IVUS) and optical coherence

tomography (OCT) can precisely measure the arc of calcium, the length of calcium and, for OCT, also the thickness of the calcific sheet,” he comments.

More data on IVL in eccentric calcific coronary lesions

In a study published in Cardiovascular Revascularization Medicine, titled “Intravascular imaging to guide lithotripsy in concentric and eccentric calcific coronary lesions,” Di Mario and colleagues showed similar outcomes in more complex real-world patients who failed other calcium modification strategies before turning to imaging-guided IVL, compared to the patients treated with de novo lesions in DISRUPT CAD I & II.

The study involved 28 patients who were selected based upon severe calcium load confirmed with IVUS or OCT. Results showed

that the final minimal stent area measured with OCT or IVUS was 7.06mm² in the eccentric lesion group and 7.13mm² in the concentric lesion group. The similarity of outcomes in eccentric and concentric lesions are consistent with the angiographic analysis from DISRUPT I and II where residual stenosis >30% was present in less than 3% with quantitative coronary angiography (QCA) in both eccentric and concentric lesions.

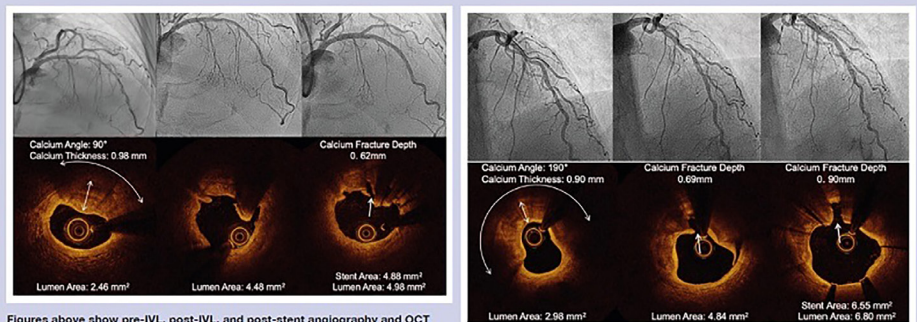
“In our centres we are constantly updating the results of this small initial single-centre series dividing the lesions based of the circumferential distribution of calcium assessed with OCT or IVUS,” explains Di Mario. “In this updated series of more than 100 calcified lesions, which is currently yet to be published, we found similar expansion post-stenting, measured with angiography and confirmed with intravascular imaging, in both eccentric and concentric calcified lesions post IVL,” he adds.

Offering a final piece of advice to his interventional cardiology colleagues as to whether they should seek to adopt IVL for eccentric coronary calcified lesions, Di Mario argues that there is “overwhelming” experience that IVL works in both eccentric and concentric lesions, but says it is for operators to draw their own conclusions based upon practical experience. “Make your own experience with IVL in eccentric lesions when you do not want to take chances,” he says. “For instance, start treating thick calcific plaques in large important vessels, especially opposite to the origin of large branches when you do not want to create large dissections and you need a predictable method to safely expand the calcium.”

This is echoed by Nef who says that due to inherent limitations with currently available devices in the treatment of eccentric lesions, “IVL provides a unique possibility also to address these specific kinds of lesions”.

IVL in eccentric and concentric coronary lesions

Representative angiography and optical coherence tomography images from DISRUPT CAD I & II cases involving an eccentric lesion (left) and concentric lesion (right). Fractured calcium is visible within the intimal and medial vessel layers for both lesions. In each example, increased lumen area is notable post-IVL treatment and post-stent.



Figures above show pre-IVL, post-IVL, and post-stent angiography and OCT imaging of eccentric and concentric lesions treated with IVL

Source: Blochitzik F, Horton B, Escaned J, et al. Safety and effectiveness of coronary intravascular lithotripsy in eccentric calcified coronary lesions: a patient-level pooled analysis from the Disrupt CAD I and CAD II Studies. *Clin Res Cardiol* 110, 238–246 (2021).